

Nutritional Pearls

40. What's a good anti-aging remedy?

***Ans.** Active H2: A natural and safe anti-aging remedy that restores homeostasis. It instantaneously converts toxic oxygen radicals to water; targets the most destructive oxygen radicals, hydroxyl and peroxynitrite without depleting the beneficial cell signaling molecules; maintains homeostatic levels of glutathione and has beneficial effects on cell metabolism and gene expression, which gives anti-inflammatory, anti-obesity, and anti-aging effects.*

X39 patch by Lifewave has been documented to stimulate stem cells!

Nutritional Pearls

41. What's the best way to restore cell membrane function?

***Ans.** Taking organic, cold pressed omega 6 omega 3 in an 11:1 ratio will rebuild the cell membranes. Your Essential Supplements.*

Nutritional Pearls

42. How to reduce or eliminate muscle spasm?

***Ans.** Several nutritional deficiencies can be the initiating factors in causing muscle spasm: low vitamin E (Cataplex E -SPL) source green peas; low magnesium (Magnesium Orotate -(Professional Formulas); low potassium (Potassium Orotate - PF); Dunaliella Salina (Arcadian Nutraceuticals): pink, single cell, micro-algae - most nutrient-dense food on earth; The Gift (Mother Earth Labs): 74 + micro and macro minerals, fulvic, humvic acids, amino acids and b-complex. Homeopathic remedy Mag Phos 30 C.*

Nutritional Pearls

43. *What's the best way to stimulate the immune system?*

Ans. *Vanish Plus: vibrationally infused energy patterns of 1,3 - 1,6 beta glucans, thymus (extract), food based vitamins A, C, E, magnesium, vegetable based essential fatty acids, L-lysine, calcium lactate (non-dairy), maca gold, adrenal and thyroid support, olive leaf, ionic silver, L-lysine, lymph drainage, quercetin, glutathione, zinc, cordyceps, and a proprietary blend of vibrationally charged immune boosters that activate the body's own defenses to engage pathogens (viruses, bacteria, mold, fungus, etc.). Vanish Plus comes in a convenient two ounce spray bottle. Dosage: Four prays orally taken three times a day away from foods allows the vibrationally infused liquid to be quickly absorbed into your bloodstream. The improved formula is also effective against COVID, any of the variants, and the flu. www.TeslaEnergy-Tec.com*

Nutritional Pearls

44. Why does use of antipyretics hamper resolution of the flu?

***Ans.** Aspirin, acetometaphen and other anti-pyretics lower fevers. When ill, you develop a fever which reduces the viruses ability to reproduce. A higher viral population slows the healing process plus enhances the spread of flu. In addition, aspirin increases the spread of viruses by increasing the permeability of cell membranes.*

During the Spanish Flu epidemic, those patients who took increased doses of aspirin were the ones who died. Also those who wore masks had a greater propensity of dying from pneumonia.

Nutritional Pearls

45. Can vertigo be treated nutritionally?

***Ans.** Yes. If the underlying cause is viral or other pathogen based. My clinical experience has been that many cases of vertigo are caused by the cytomegalovirus, which came from root canal teeth. Cat's Claw is one of the best herbs that is very effective in resolving CMV infections.*

Nutritional Pearls

46. *What does bleeding gums and bruising have in common nutritionally?*

Ans. *Vitamin C deficiency. Capillary fragility. Use of bioflavonoids like Cyruta Plus (SPL) and Chlorophyll Complex (SPL) strengthens the blood vessel walls and stop both bleeding gums and bruising easily. One to three months.*

Nutritional Pearls

47. *Can gall stones be treated nutritionally?*

Ans. *Yes. Gall stones are comprised of cholesterol, which precipitates out from the bile. Following a 6 to 8 week protocol of taking choline (SPL), AF Betafood (SPL), apple juice (malic acid), and including into the diet fresh steamed beets and beet tops one can soften the gall stones and flush them out using 2 ounces of extra virgin olive oil, 2 ounces of freshly squeezed grapefruit juice and a 1/4 teaspoon of $MgSO_4$ (Epsom salts). Drink mixture and place a hot water bottle over the gallbladder for a half hour.*

Nutritional Pearls

48. Can cholesterol be lowered nutritionally with vitamin A?

***Ans.** Yes. Vitamin A Complex (SPL) derived from beef kidney fat is high in arachadonic acid, which is a cholesterol-metabolizing substance. There are 14 different isomers of vitamin A. Fish oil derive vitamin A will NOT work.*

Nutritional Pearls

49. *What does insomnia and constipation have in common nutritionally?*

Ans. *Cataplex B (SPL). When patients have a difficult time staying asleep, it may be caused by a build up of lactic and pyruvic acids during the night. An increase in these waste products stimulate the adrenals awakening the patient. Constipation sometimes is due to a lack of smooth muscle tone which is needed in peristaltic action to move waste products along the intestines. Cataplex B contains B1, B4, B6, B12 all of which tone up smooth muscles increasing motility of the intestines. Also check out hypothyroidism.*

Nutritional Pearls

50. Can kidney stones be resolved nutritionally?

***Ans.** Yes. Patients who form bladder or kidney stones often have urine that is on the alkaline side. Acidifying them with an acid ash mineral like Phosfood Liquid (SPL) will help dissolve the stones. To help prevent further stones from forming, magnesium and B6 should be added to their supplement program.*

Nutritional Pearls

51. Can blindness be reversed?

***Ans.** It depends on the initiating factor(s.) In my clinical experience, I have found CMV (cytomegalovirus) as the underlying cause for blindness. The root cause must be determined by Quantum Testing and the appropriate remedies used. Cat's Claw and other food based supplements must be tested.*

PHYSIOLOGY OF CELL PHONES

52. How to counteract the damaging effects of cell phones.



They actually induce an enzyme in your brain called ornithine transcarbamylase which generates nitric oxide synthase which creates proxynitrate that cooks glial cells and makes your brain cells die. *William Deagle, MD*

*Molecular Hydrogen is the strongest antioxidant & the smallest molecule in the world. Molecular Hydrogen is a gas (H₂). It is one of the few molecules able to penetrate the blood-brain barrier allowing it to seek out the worst and most damaging types of free radicals. Also take **Astaxanthin**.*

Dental Cancer Connection

Defining the Initiating Factors

CANCER

is not a Disease!

It is a breakdown of the immune system, an oxygen deficiency problem, and an adaptation to toxicity.

Based on the 1920s research of William F. Koch, PhD, MD
and Otto Warburg, MD, Ph.D.'s 1931 Nobel Prize in
Physiology for discovering hypoxia as the cause of cancer

THREE MECHANISMS THAT TRIGGER OFF CANCER

1. Corrupted cell membranes due to adulterated omega 6 oils.
2. All carcinogens scramble specific ultra violet wavelengths, which prevents repair of the DNA.
3. When the oral pH reading dips to 5.24, the body's cell membrane potential reads +55 millivolts, which damages the DNA and triggers the proliferation of cells: cancer.

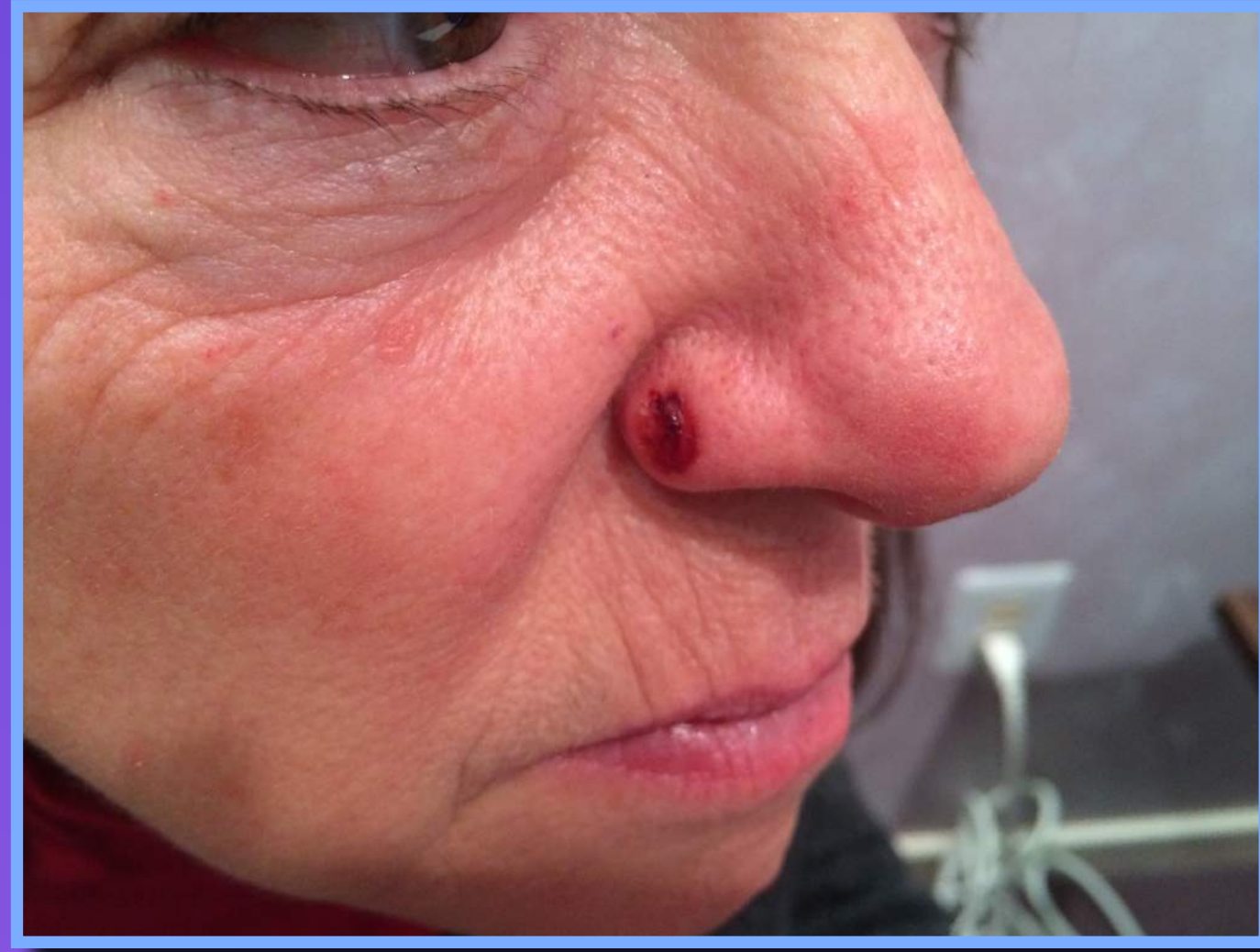SCIENTIFIC DOCUMENTATION FOR THE THREE MECHANISMS THAT TRIGGER OFF CANCER

- In 1931, Otto Warburg, MD, PhD won a Nobel Prize in Physiology for discovering cancer was caused by hypoxia (low oxygen); when the body's pH became too acidic (below 6.5), it initiated fermentation. Keith Brewer correlated the oral pH to cell membrane potential and found that a +55 millivolt cell membrane potential damaged DNA and triggered off cell proliferation - cancer.
- In the 1970s, Dr. Fritz Albert Popp discovered that all carcinogens scramble specific ultraviolet wavelengths, which repairs the DNA.
- In 2015, Prof. Brian S. Peskin's book, *PEO Solution*, provided the documentation that cell membranes become corrupted by the adulterated omega 6 oils in our diet, turning them into plastic, and prevent oxygen and nutrients from entering the cells and metabolic wastes from exiting.

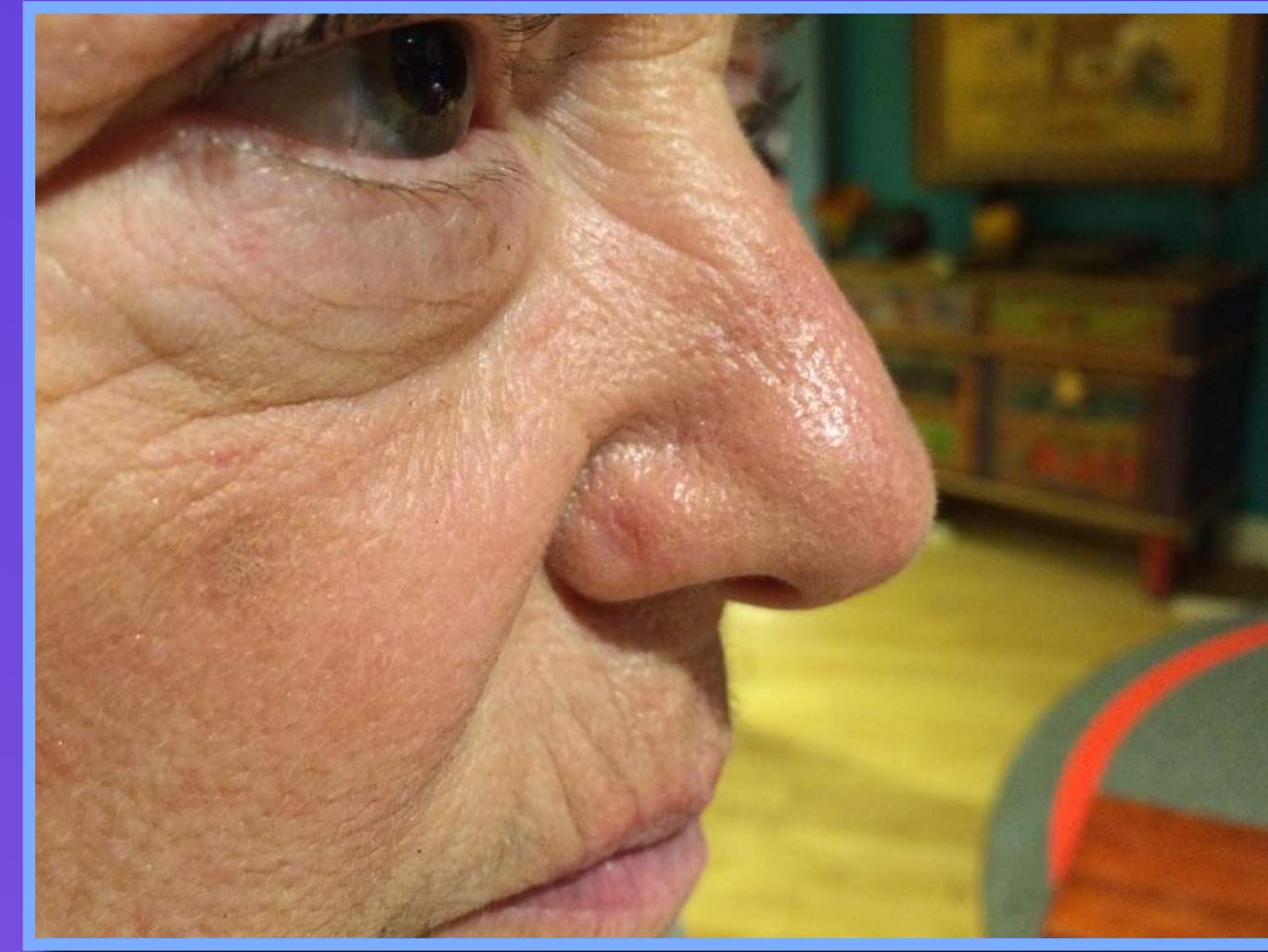Basal Cell Carcinoma

CyberScan Professional System

Does scalar frequency technology really work?



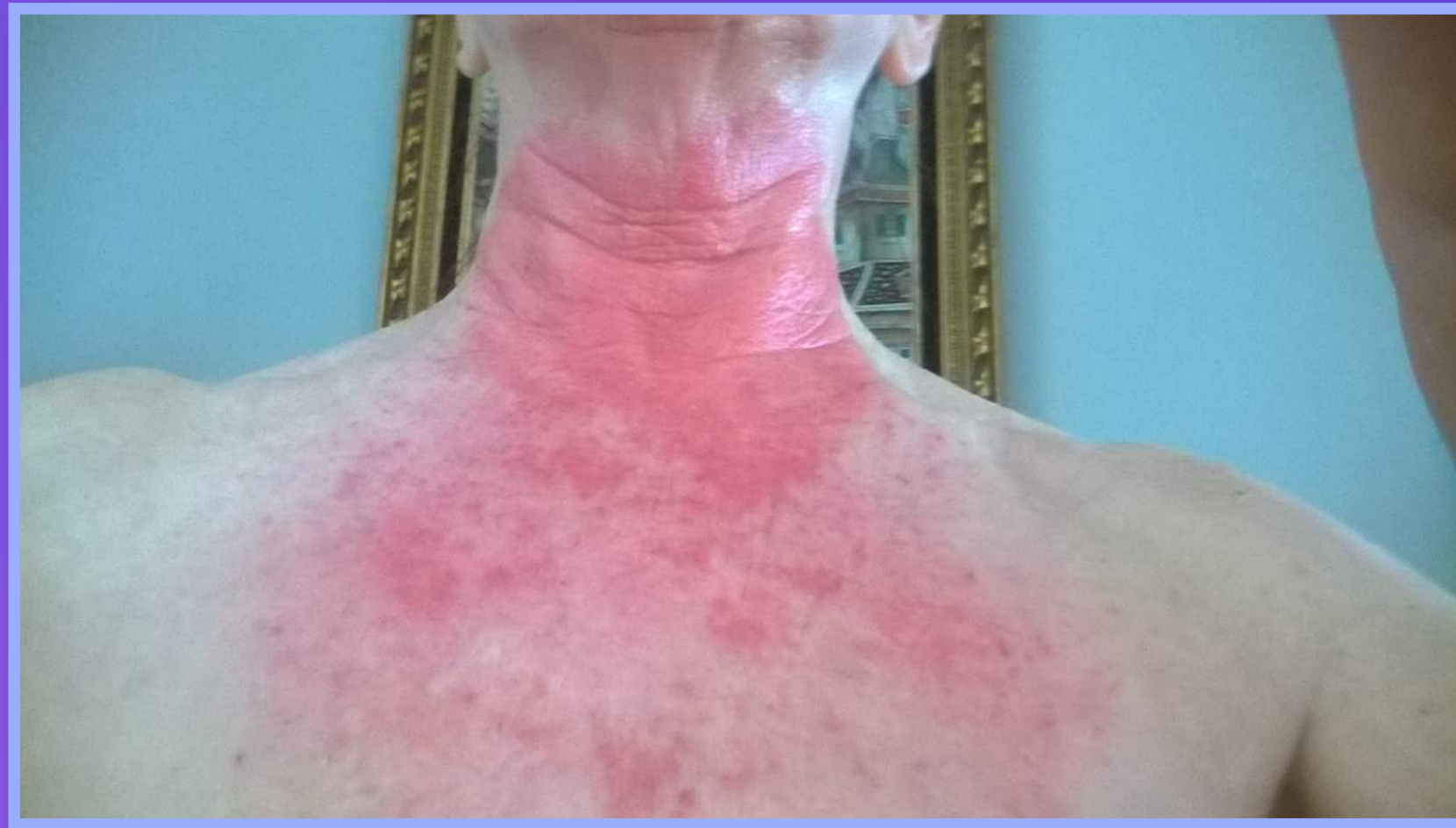*Basal Cell Carcinoma
Pre-Tx*



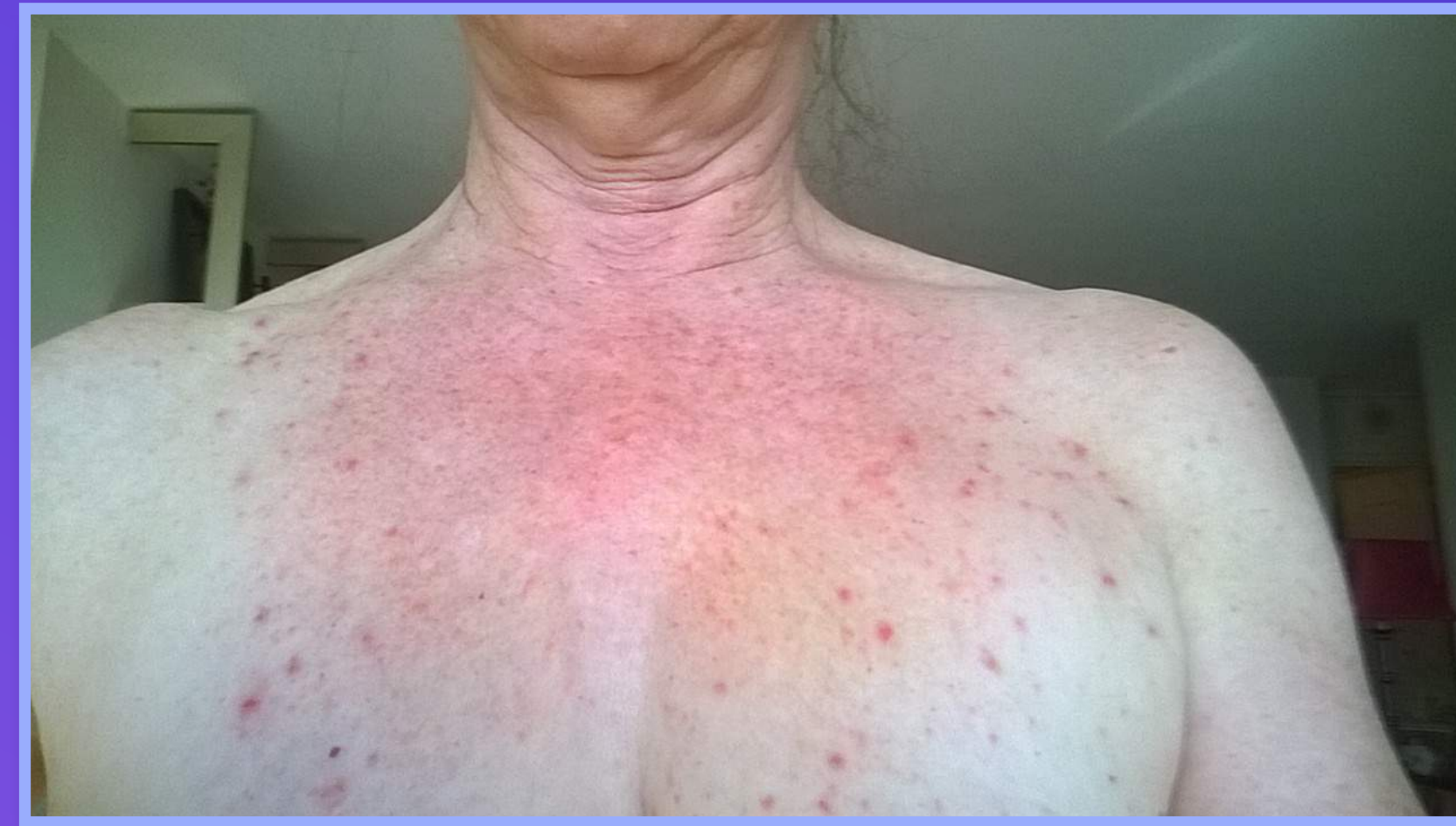*Basal Cell Carcinoma
15 months Post-Tx CyberScan
and nutritional therapy*

CyberScan Professional System

Detox reaction from CyberScan Tx and vitamin therapy



Mercury detoxing from thyroid



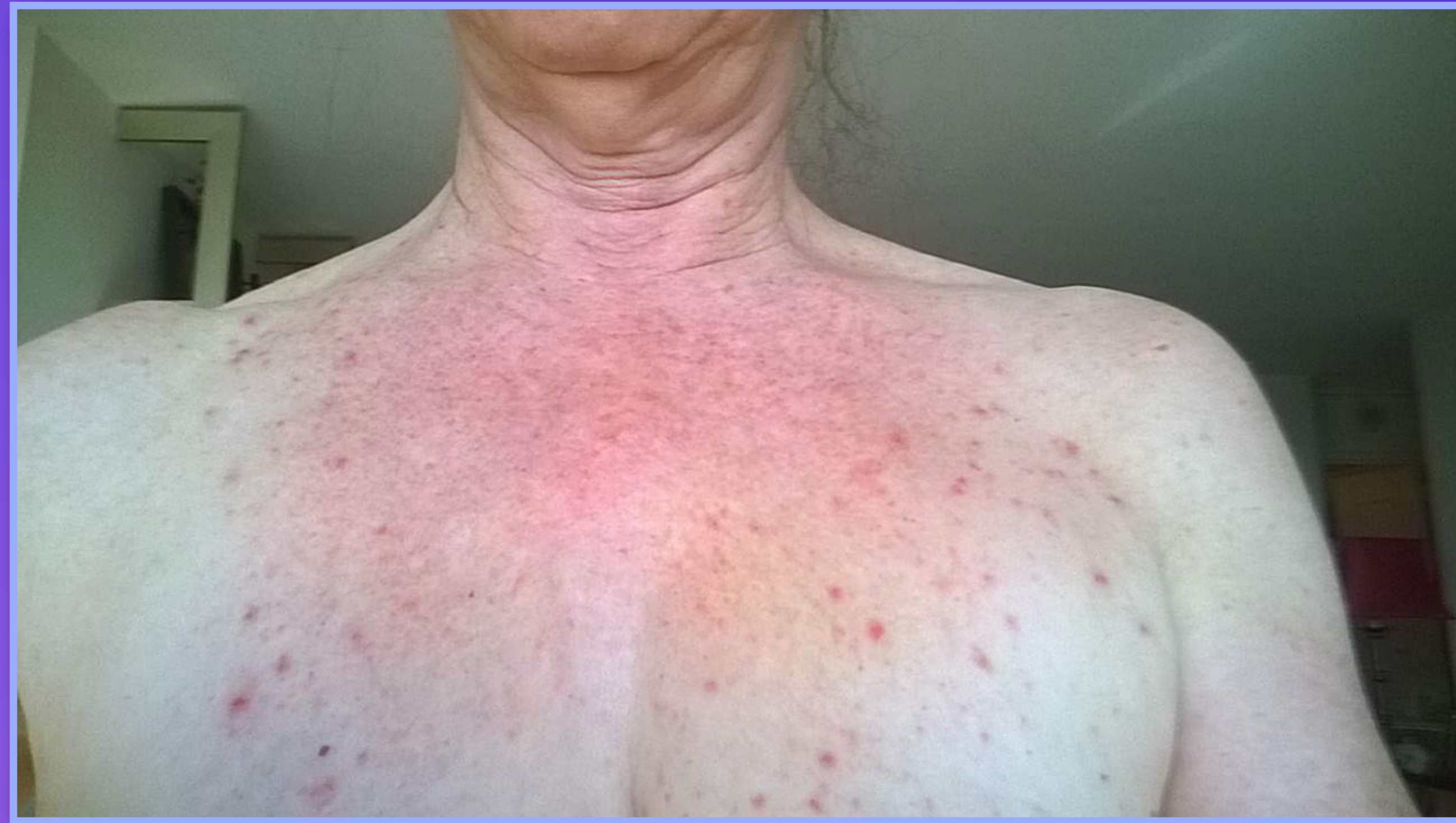Later stage of detox

Mercury was present in the basal cell lesion as well as many other toxins.

CyberScan Professional System

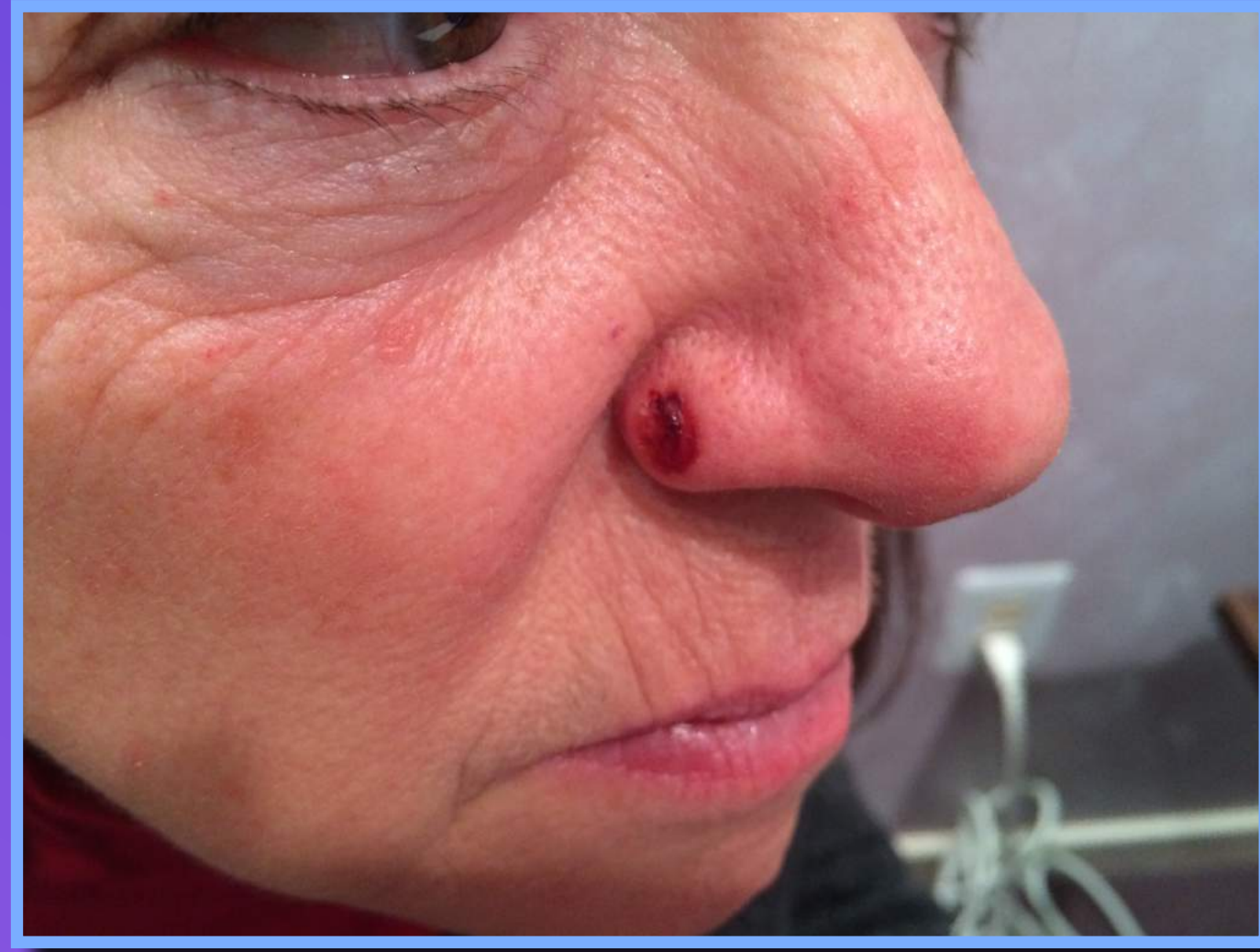Detox Reaction From Supplements

Third stage of detox

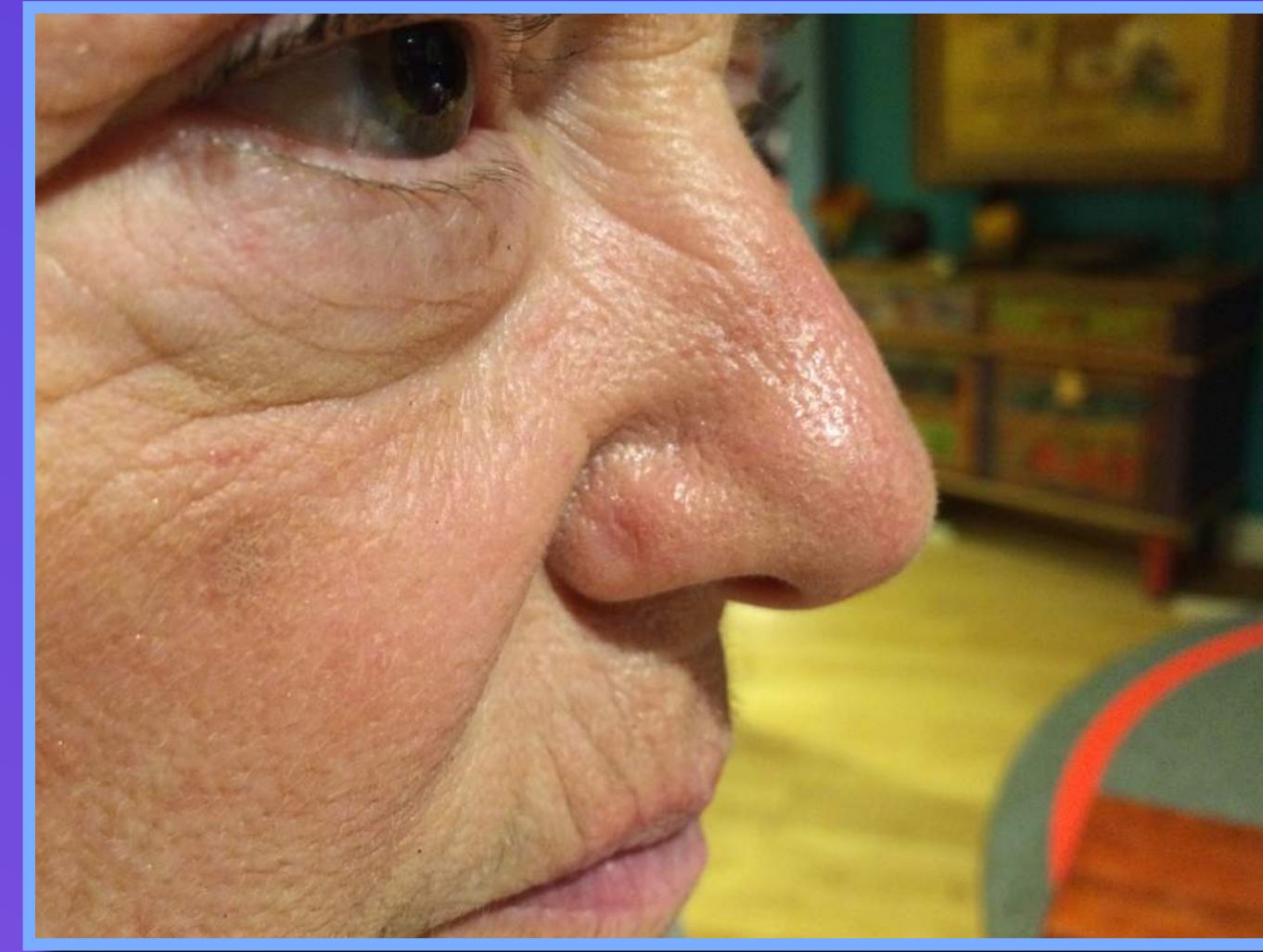

Chief complaint was severe itching due to toxins exiting the body (candida, pesticides, heavy metals, vaccines, etc.)

Remove the “Splinters” and Watch the Body Heal

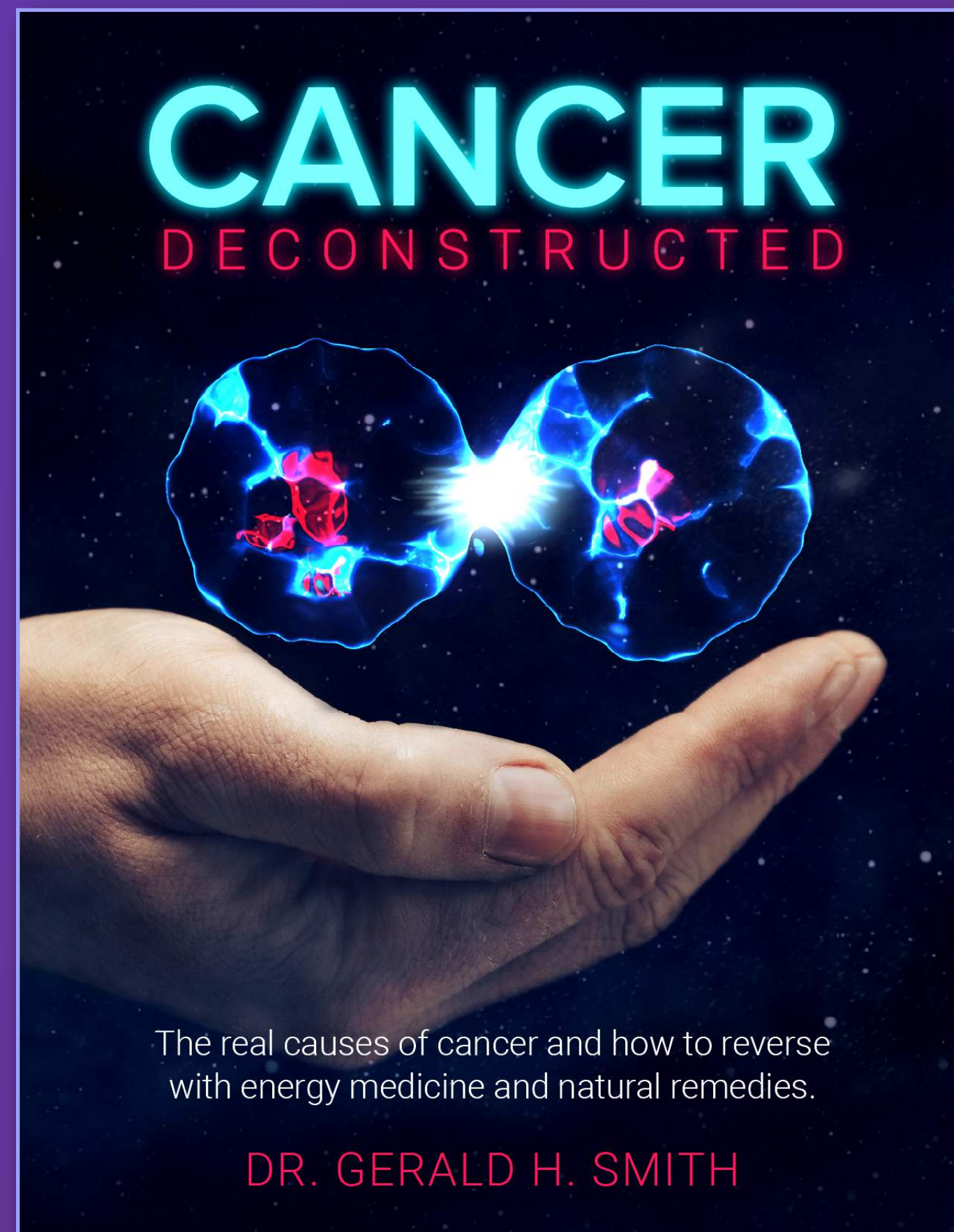


*Basal Cell Carcinoma
Pre-Tx*



*Basal Cell Carcinoma
15 months Post-Tx CyberScan
and nutritional therapy*

LATEST BOOK RELEASE



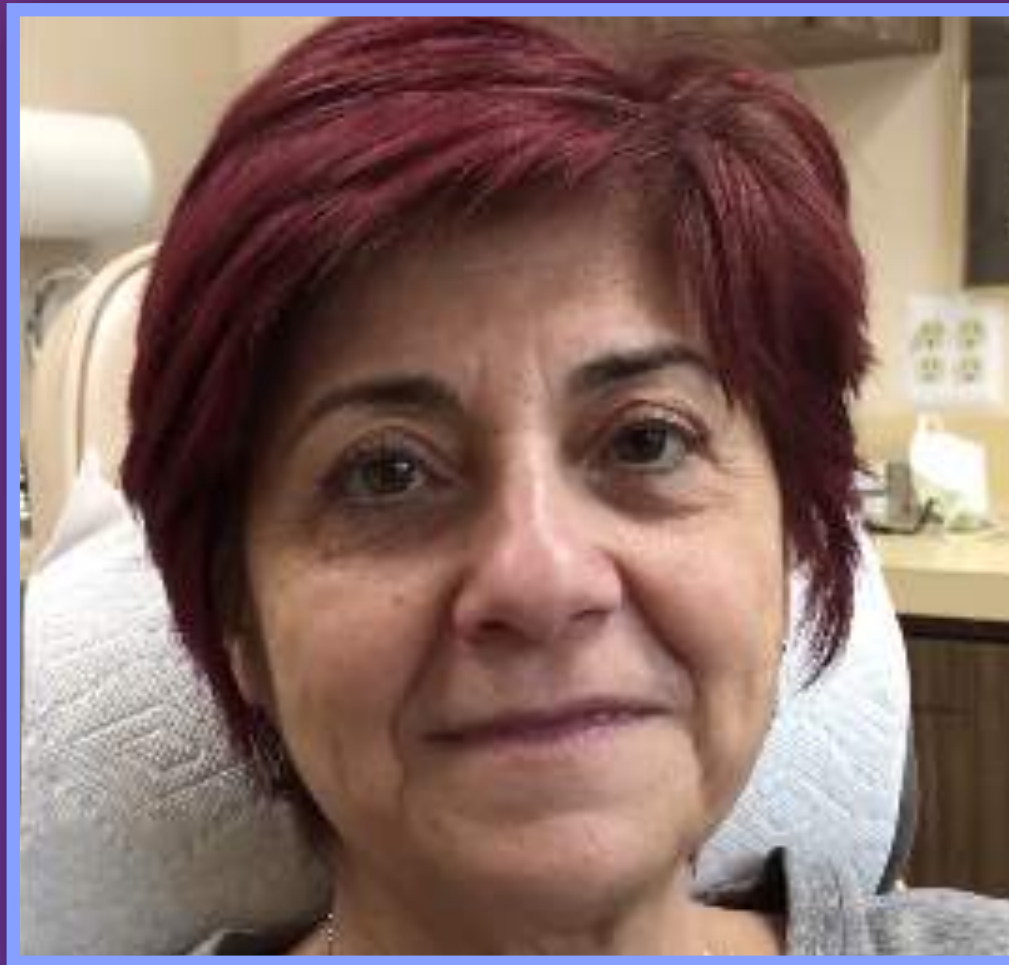Information the AMA, FDA, and Big Pharma do not want you to know!

This book exposes the medical industry's illusion about cancer and the chemotherapy treatment hoax. It Provides the three scientific mechanisms that initiate cancer and how to reverse them. A must read for anyone who has cancer or anyone who wants to take steps to prevent it.

Available: print version or download e-book at www.icnr.com

Lung Cancer
Root Canal
Cancer Connection

CARCINOMA RIGHT LUNG

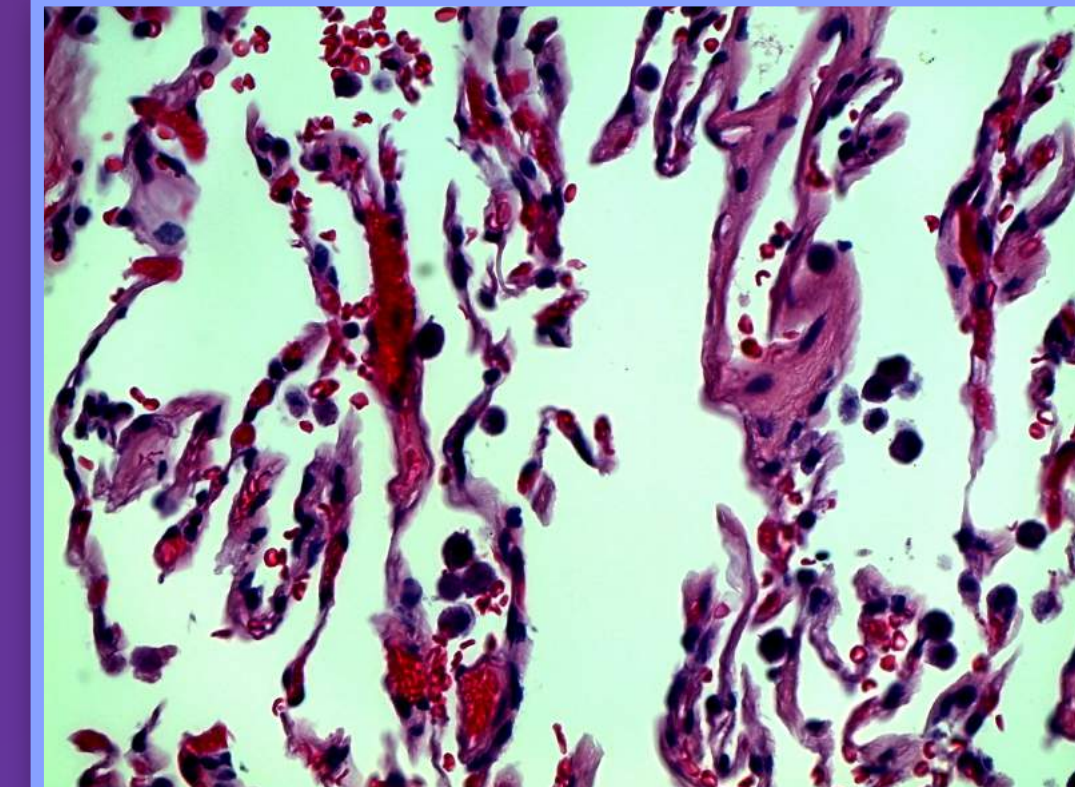
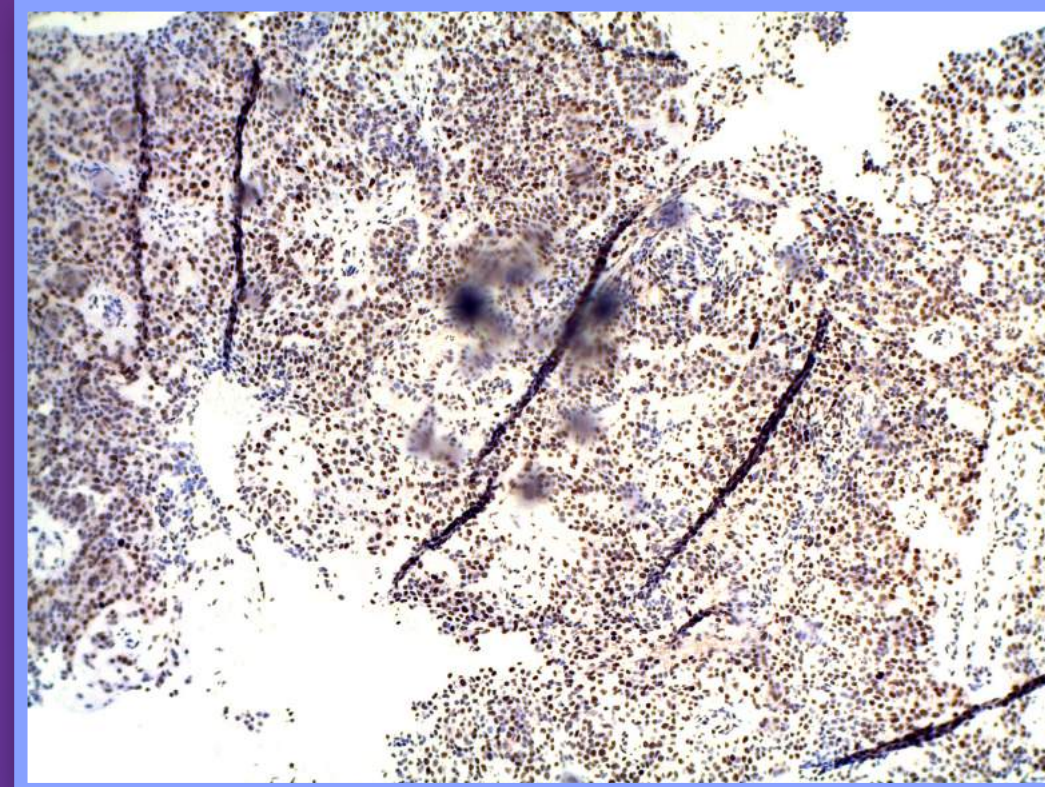
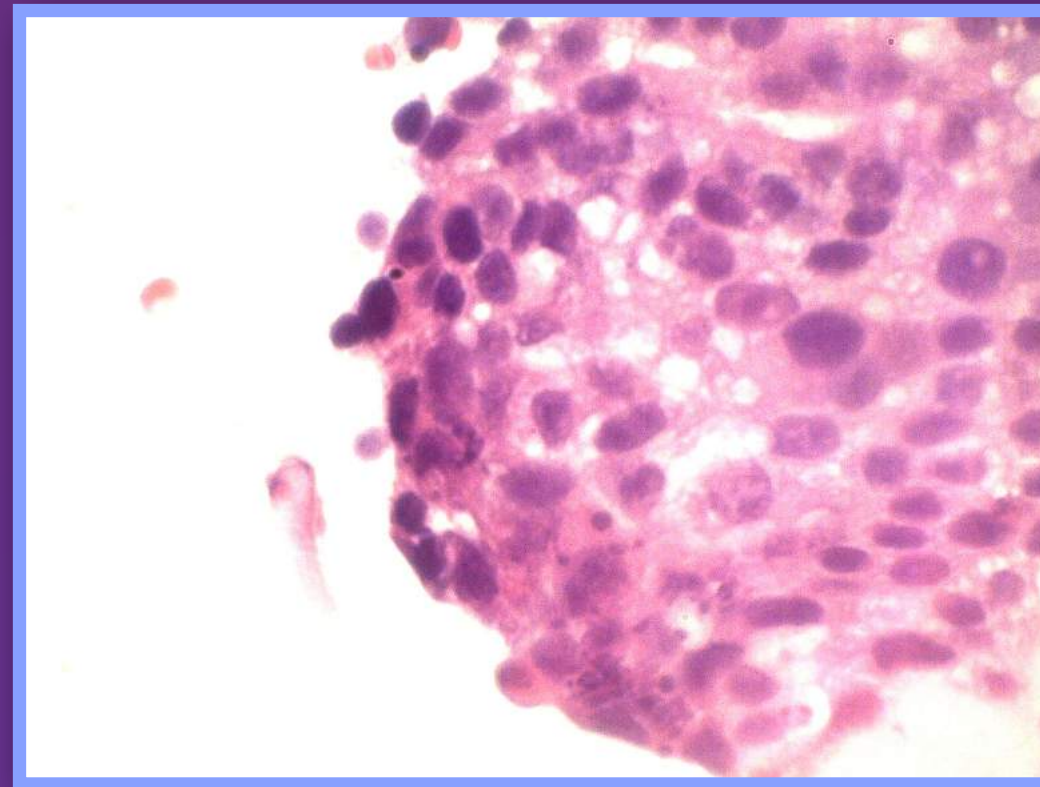
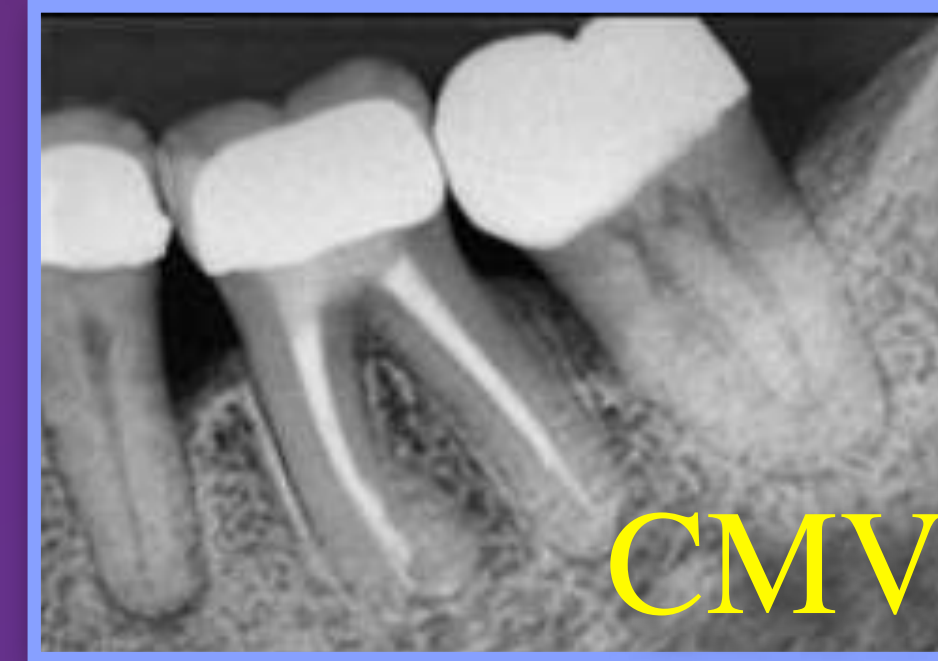


Carol K. developed right lung cancer. **Traditional Tx:** cut tip of right lung off where the cancer was present. The patient refused chemo or any other conventional Tx. Six months later the cancer appeared in the left lung. Patient refused any surgical intervention. Carol was referred to my office by her chiropractor.

Case Study #87 - all case studies can be reviewed at www.icnr.com

LUNG CANCER

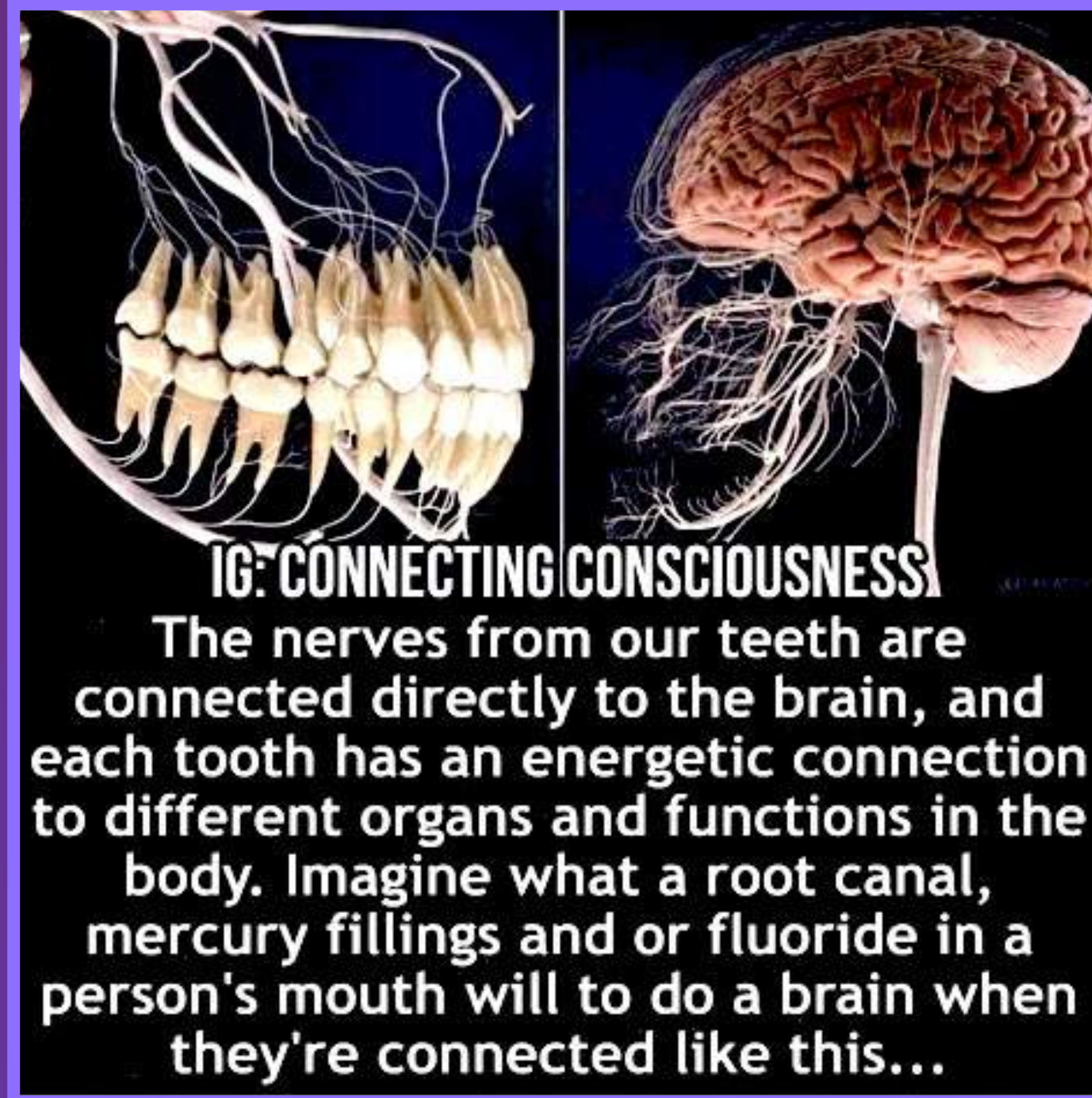
Pathology slides were tested energetically



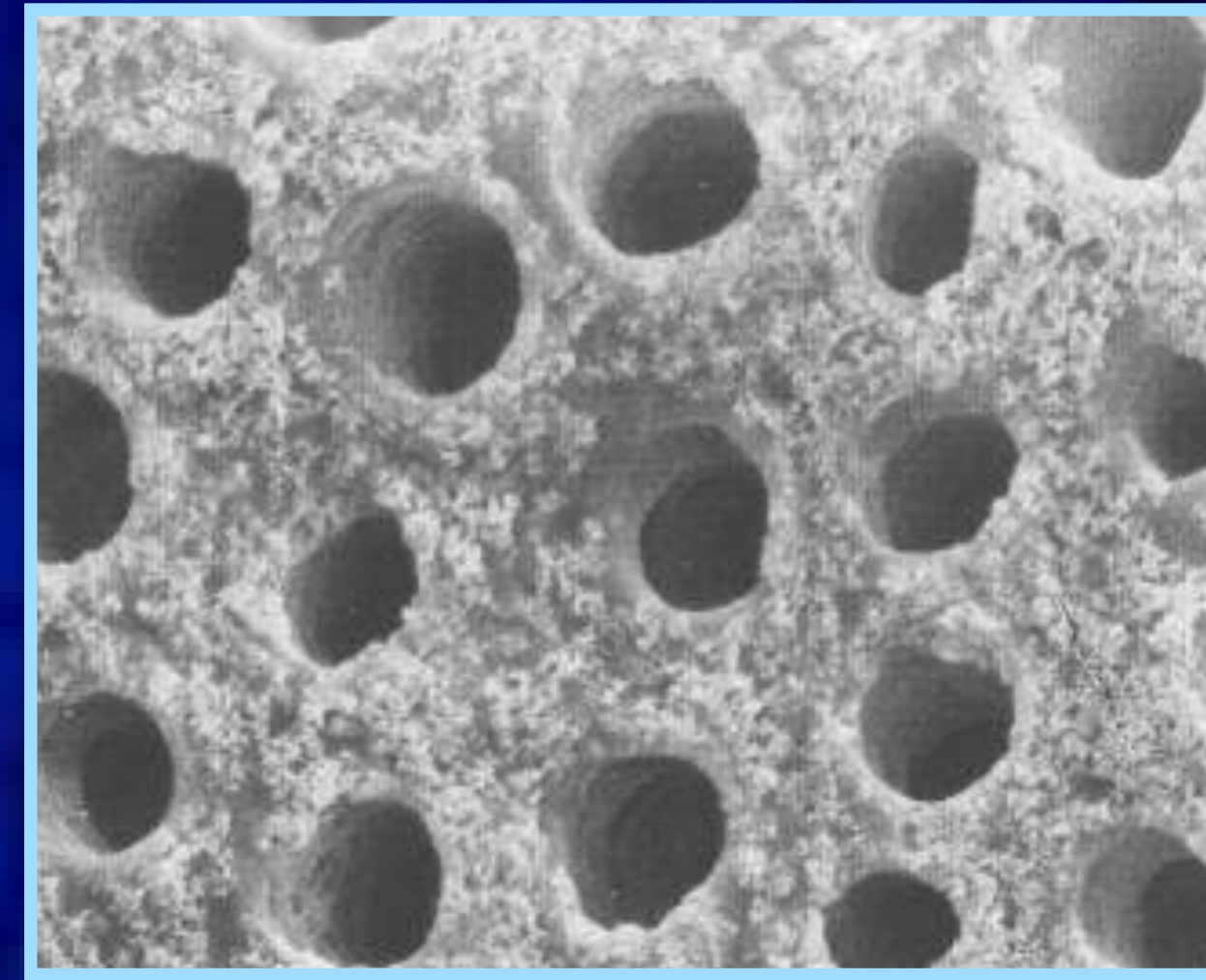
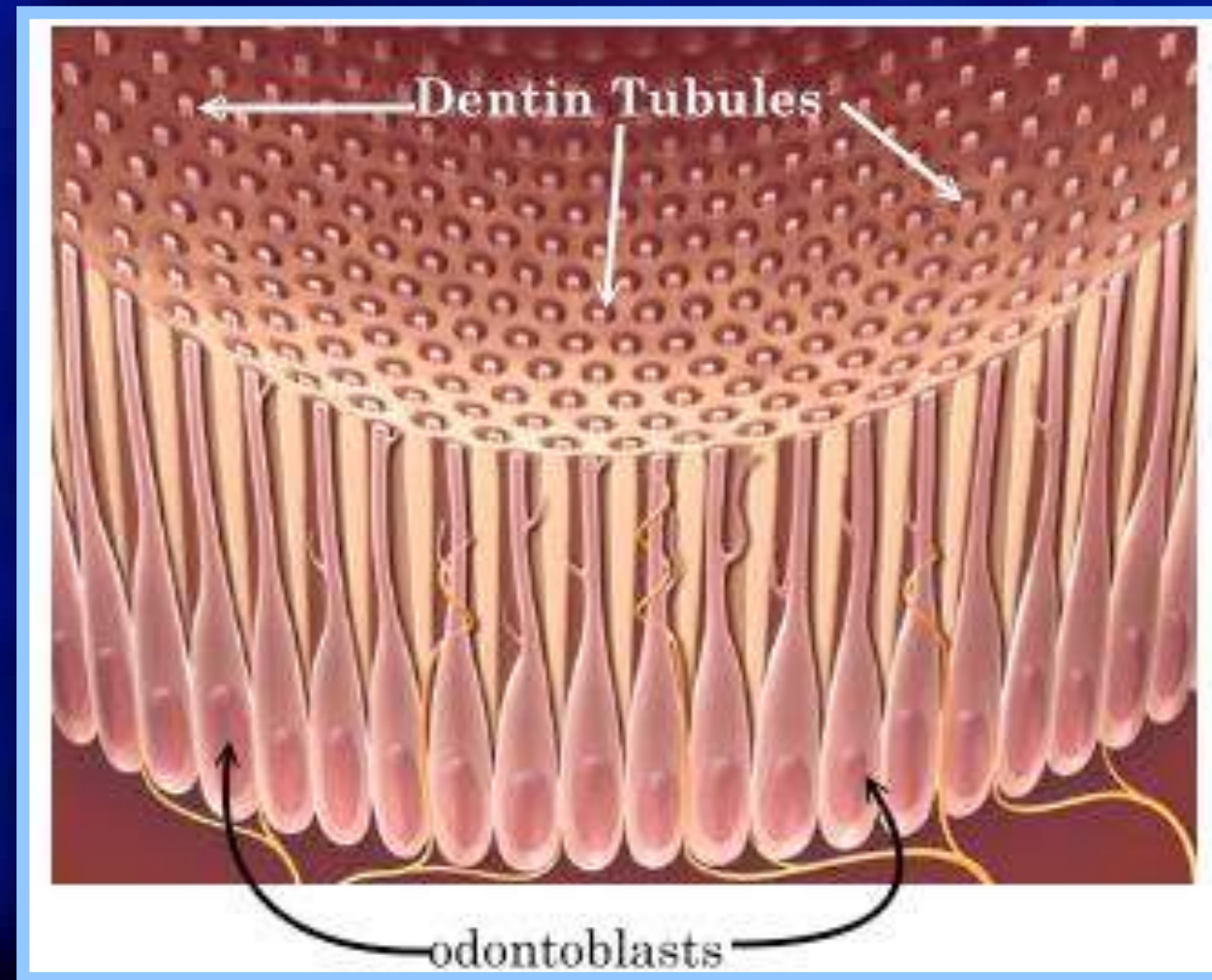
Quantum Testing Dx: CMV, Hg, and a pesticide in the cancerous tissue!

Remove the “Splinters” and Watch the Body Heal

THE TEETH ARE DIRECTLY CONNECTED TO THE BRAIN

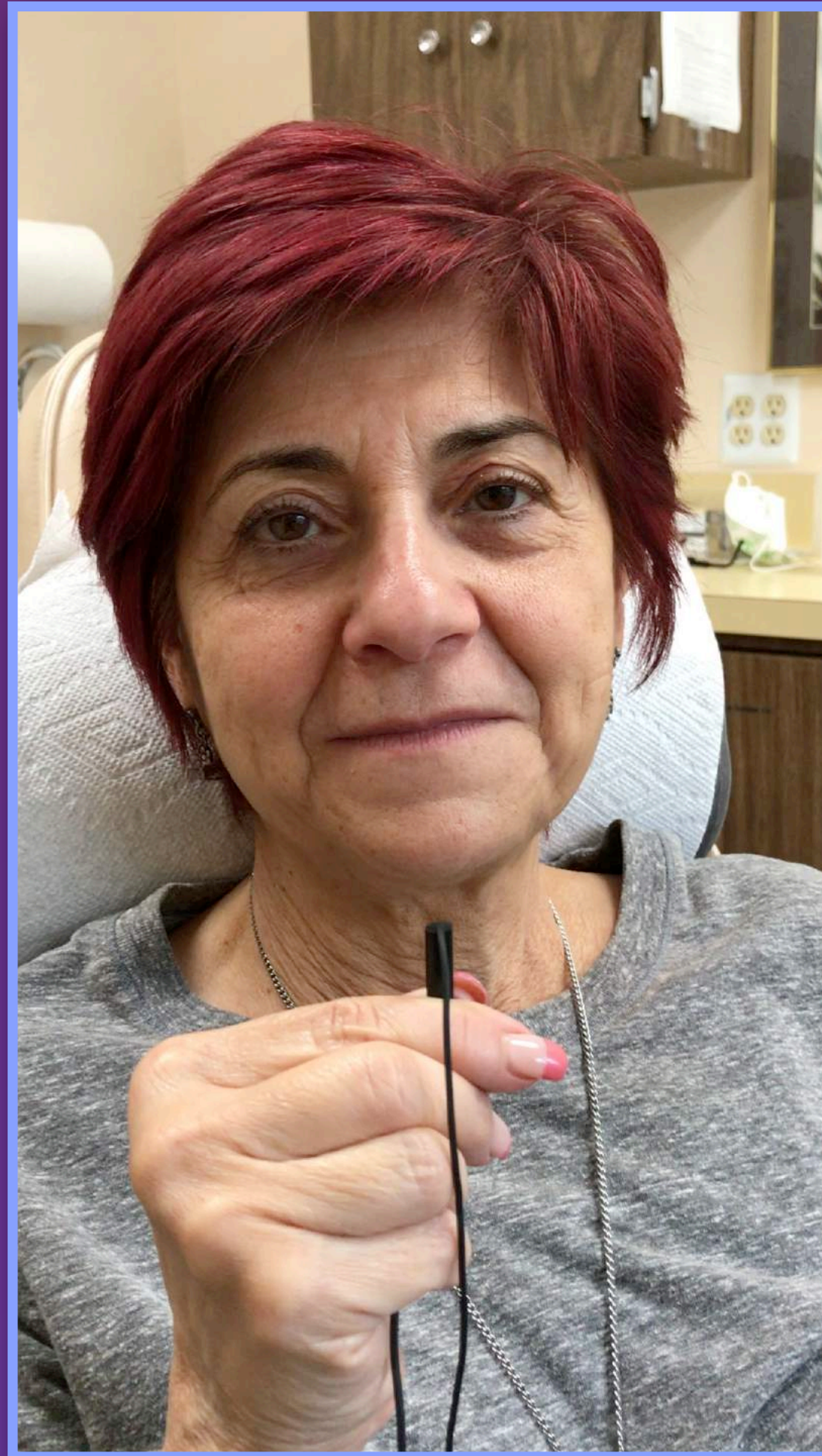


Dental Connections



A molar tooth has approximately 3 miles of dentin tubules. Root canal teeth have been documented to have millions of bacteria with 400 different bacterial species. The released toxins function to suppress the immune system.

LEFT LUNG CANCER



Carol K. was placed on a nutritional program to detox her liver, open up drainage, chelate the Hg, pesticide, and remove the CMV. Also the mandibular left molar was extracted. Extraction site **Tx:** O₃, Ionic Ag, Sanum remedies that were tested compatible for the patient.

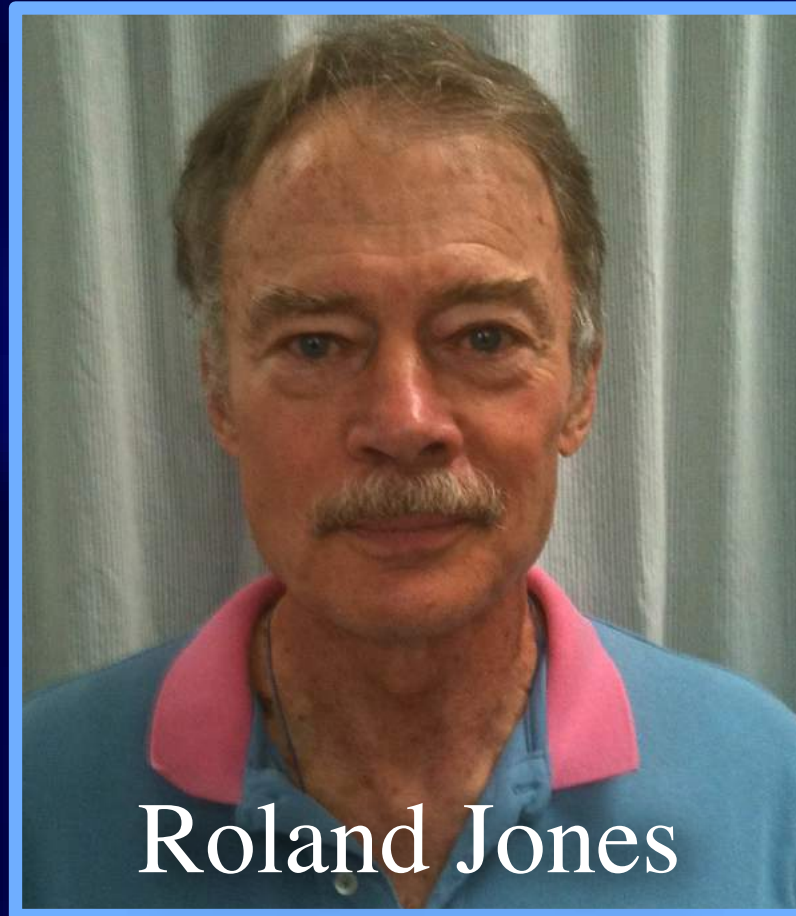
Additional Tx: Theraphi, Rife frequencies, and CyberScan.

The squamous cell carcinoma disappeared totally in six months and the patient has been cancer free for over six years!

Stage IV Throat Cancer

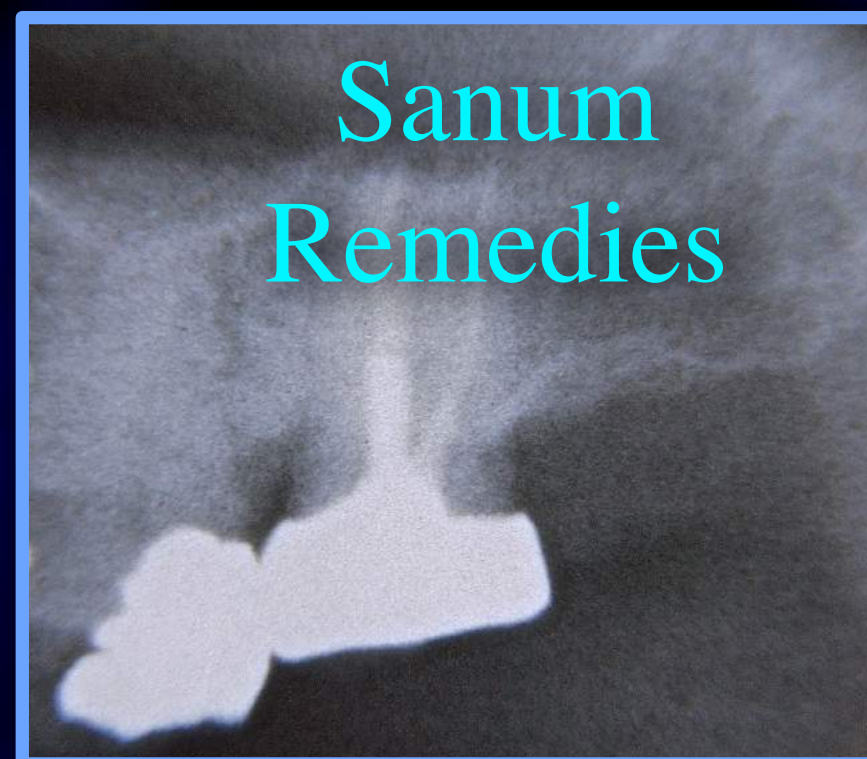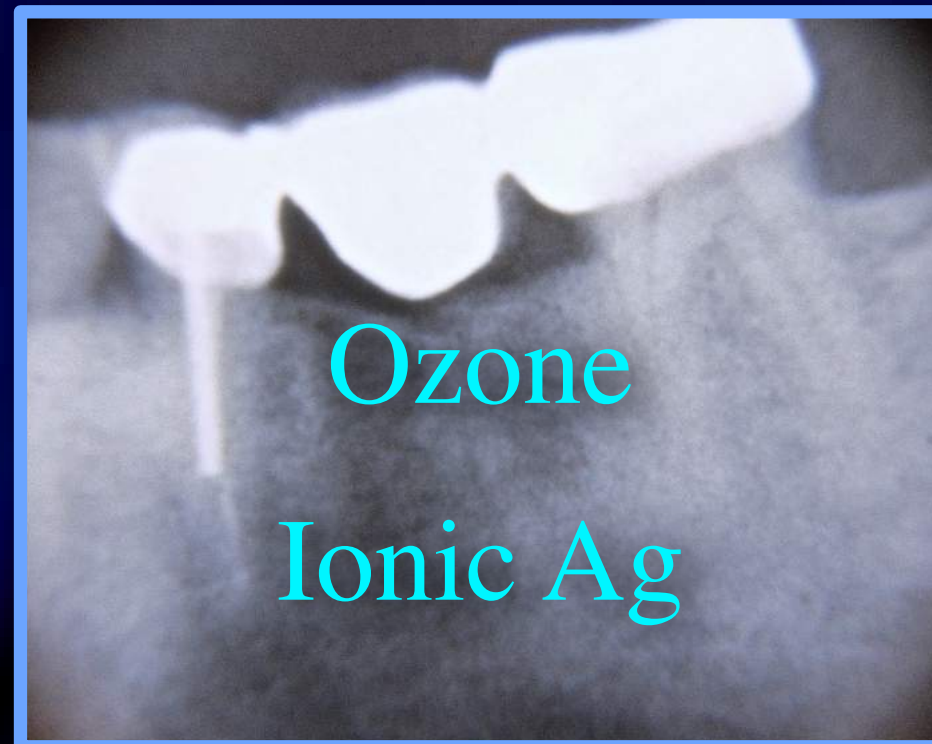Root Canal Cancer Connection

Cancer Dental Connection



Roland had documented stage IV throat cancer with bilateral swollen cervical lymph nodes.

DX: Three infected teeth were present: lower left second bicuspid and second molar and maxillary left second molar. The same pathogens (Strep viridans and Tuberculinum) present in the three teeth were also present in the swollen cervical lymph nodes and throat cancer.



Tx: Extraction of the three infected teeth, Rife frequencies, raw juices, food based supplements and IPT totally resolved the cancer in three weeks. Roland has been cancer free for over 11 years.

PET Scan Report

07/15/09 13:47 ST. MARY MEDICAL CENTER (215) 710-2000 Page 1

St. Mary Medical Center
1201 Langhorne-Newtown Road Langhorne, PA19047
215-710-2185
Diagnostic Imaging

PATIENT NAME: JONES,ROLAND S
MED REC NO:M009211786
ACCT NO.:LP0307111088
ORDER NO:0715-0007

DOB:07/01/1940 AGE:69 SEX:M
PT CLASS:REG CLI
PT ROOM/BED:
DEPT: Pet

ORDERING DR.: CHACK, BENJAMIN S DO
CC:CHACK,BENJAMIN S DO; KIPP,JOSEPH MD;

ATTENDING DR.: CHACK,BENJAMIN S DO

REASON FOR EXAM: CA OROPHARYNX
COMMENTS:
ADMITTING REASON: OPOPHARYNX CA

PREGNANT: LMP:

ORDERED DATE/TIME: 07/15/09 1029
REPORT DATE/TIME:07/15/09 1346

PROCEDURE: PET/CT Skull to Thighs
REPORT NO.: 0715-0366

Status: Signed

Whole-body PET scan dated 07/15/09

History: Oropharyngeal cancer

Attenuation corrected imaging of the neck, chest, abdomen and pelvis was performed on a dedicated PET scanner following intravenous injection of 8.77 mCi of FDG. Blood glucose was 106 at the time of injection. Small field-of-view scan of the head and neck region is again performed, in addition to whole-body PET scan. Comparison is made to prior study of April 22, 2009.

Neck: Previously described asymmetry of the right tonsil remains stable in appearance. There is no evidence for new mass-effect or mass. Again noted is a minimal amount of nonspecific FDG uptake along the right pharyngeal and lingual tonsils, with maximum SUV in the range of 3.5. There is no evidence to suggest recurrent or residual focally increased FDG uptake or adenopathy within the neck.

Chest: Negative

Abdomen: Negative

Pelvis: Negative

Bone marrow: Negative

Impression:

1. Again noted is mild residual asymmetry and mild increased nonspecific FDG uptake associated with the right pharyngeal tonsillar region, unchanged from the prior study of April 2009. There is no evidence to suggest recurrent or increasing oropharyngeal mass. There is no evidence for developing cervical adenopathy or other metastatic disease.

TECHNOLOGIST: MCM
READING DOCTOR: COHEN,DANIEL J MD

SIGNED: COHEN,DANIEL J MD
PRINTED: 1347

PAGE:1 OF 1
PATIENT NAME:JONES,ROLAND S
MR#: M009211786
REPORT#:0715-0366

July 15, 2009

Oropharyngeal Cancer

Examination Report

September 3, 2009

September 3, 2009

Joseph Kipp M.D.
Village At Newtown Medical Center
2700 South Eagle Road, #100
Newtown,PA 18940

RE: Roland Jones
DOB: 07/01/1940

Dear Dr. Kipp,

Roland Jones was seen for followup today.

Enclosed are my findings:

Vitals: BP: 135/93 Pulse: 85

CC: Patient presents for throat pain.
HPI: no new complaints , status post carcinoma of neck

Exam:
ENMT:

Ears: External Ears: Inspection reveals normal ears. Canals within normal limits, but no cerumen in the auditory canals Tympanic membranes: intact and normal mobility.

Nose: External nose WNL. Internal Nose: Nasal cavity clear. Mild deviation of the nasal septum. Bogginess, hypertrophy and pallor of the turbinates bilaterally.
Oral Cavity: Lips appear normal and healthy. Dentition is in good repair. Gums appear healthy. Examination of the tongue appears normal. Submandibular and parotid ducts are patent bilaterally. Hard palate normal in appearance.

Oropharynx: Appears normal. Examination reveals base of tongue is soft, but does not reveal base of tongue mass. Soft palate normal in appearance. Uvula midline and normal in size. Tonsils , right tonsillar fossa within normal limits
Posterior pharynx is normal.

Neck: Palpation reveals crepitation of the midline cartilages, but no tenderness.
right neck mass, resolved Trachea midline. Thyroid is normal to palpation.

No Evidence of Disease

Assessment #1: 146.9 Cancer Of Oropharynx

Plan:

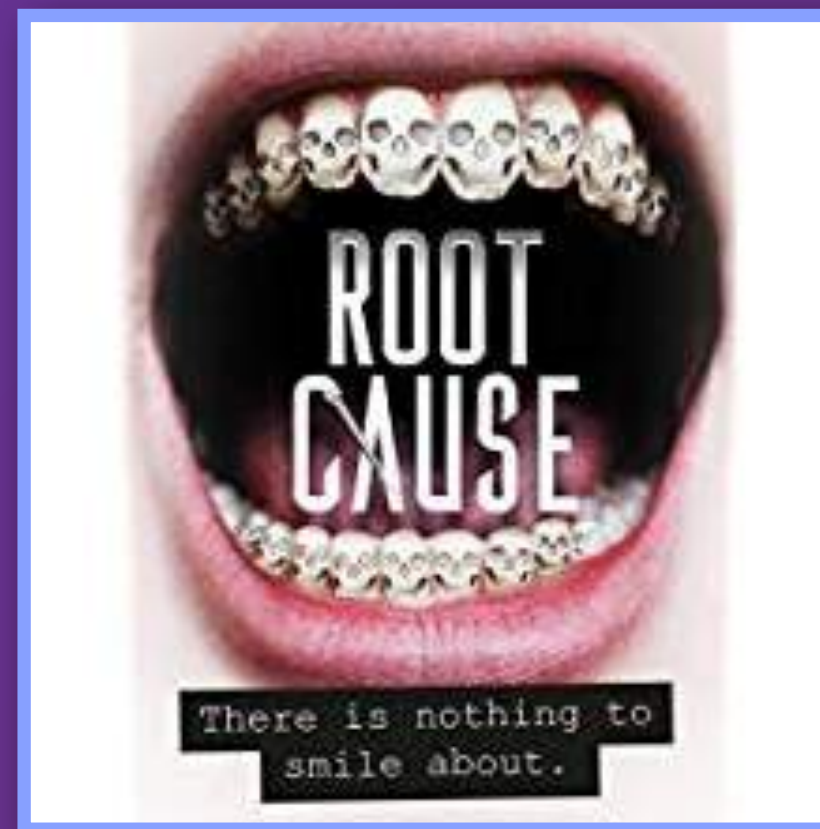Comments : No Evidence Disease, will observe and follow up in 2 months

DOCUMENTARY

Root Cause

Band from Netflix

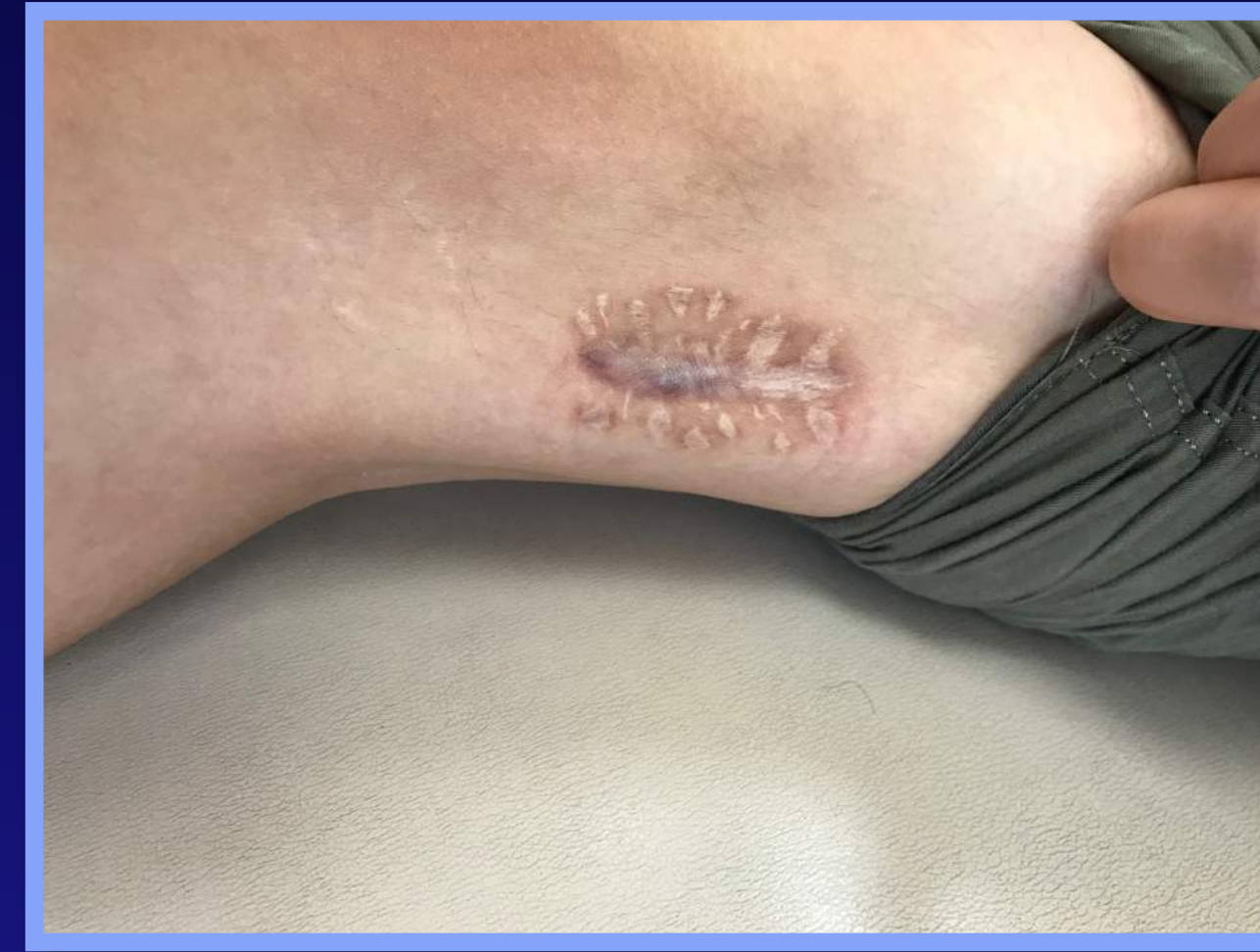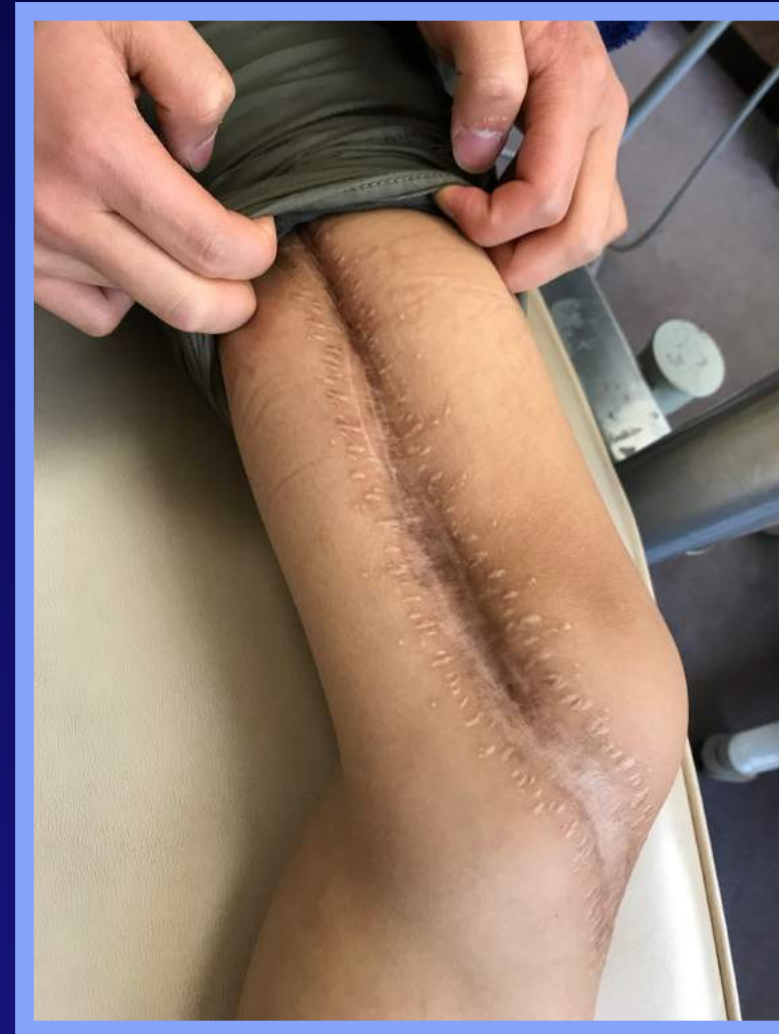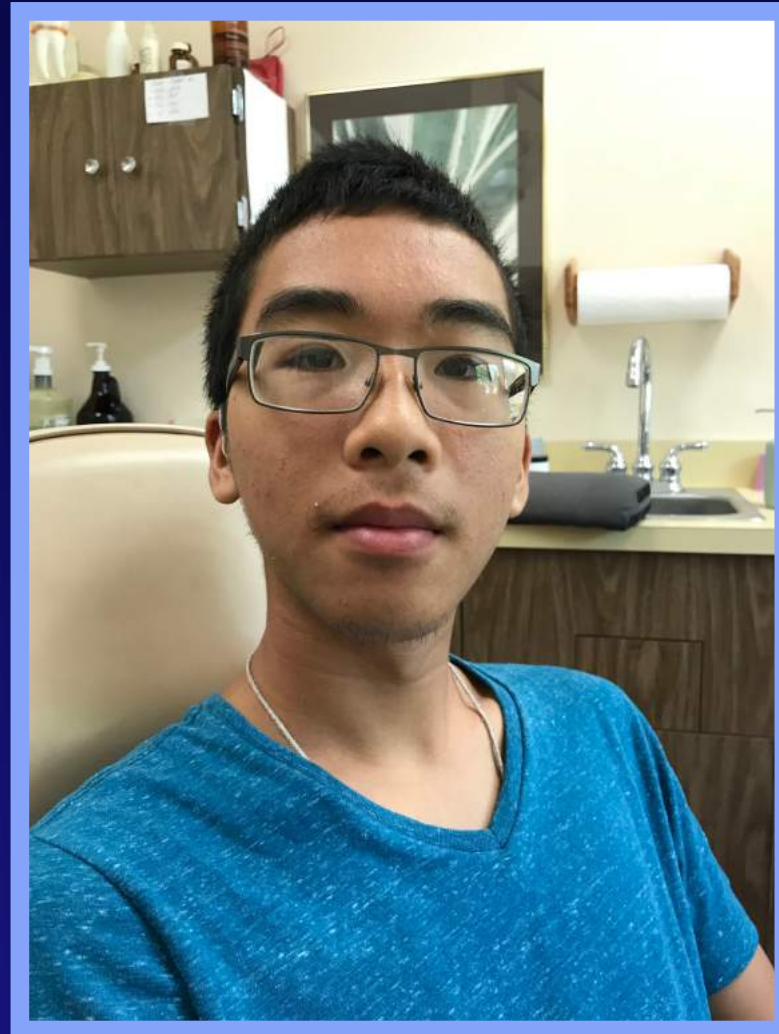Can purchase it on Amazon



www.icnr.com/articles/root-cause-documentary.html

Osteosarcoma of the Left Leg

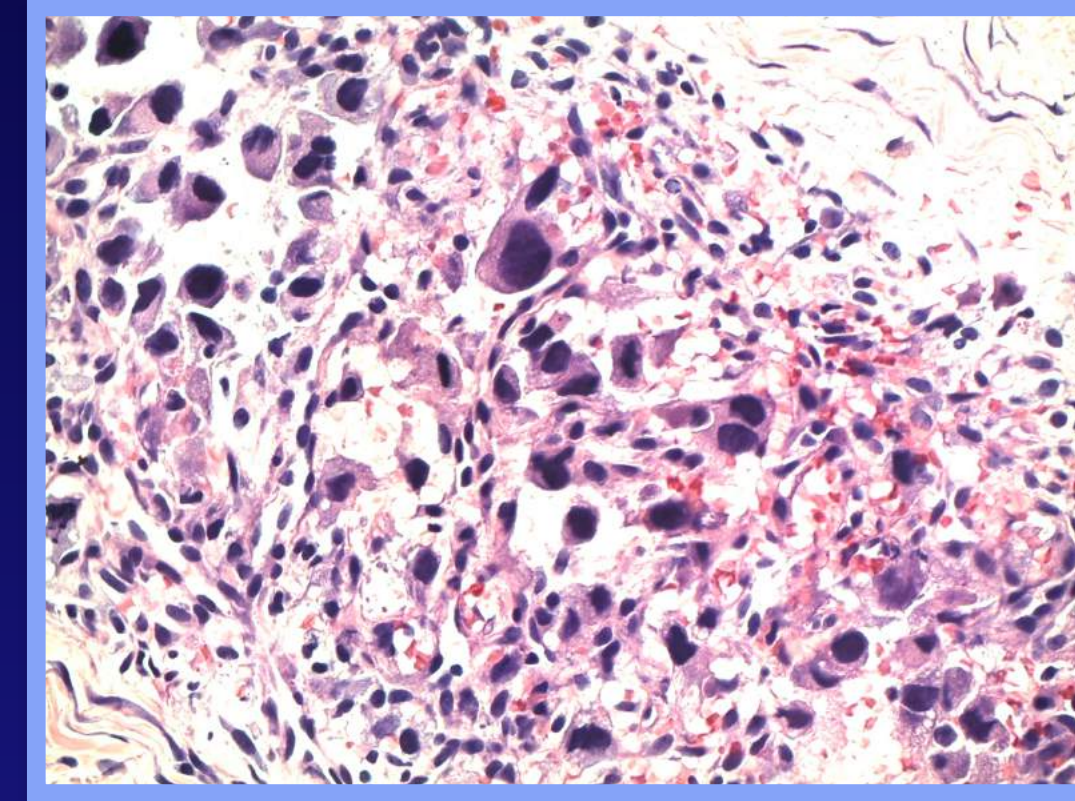
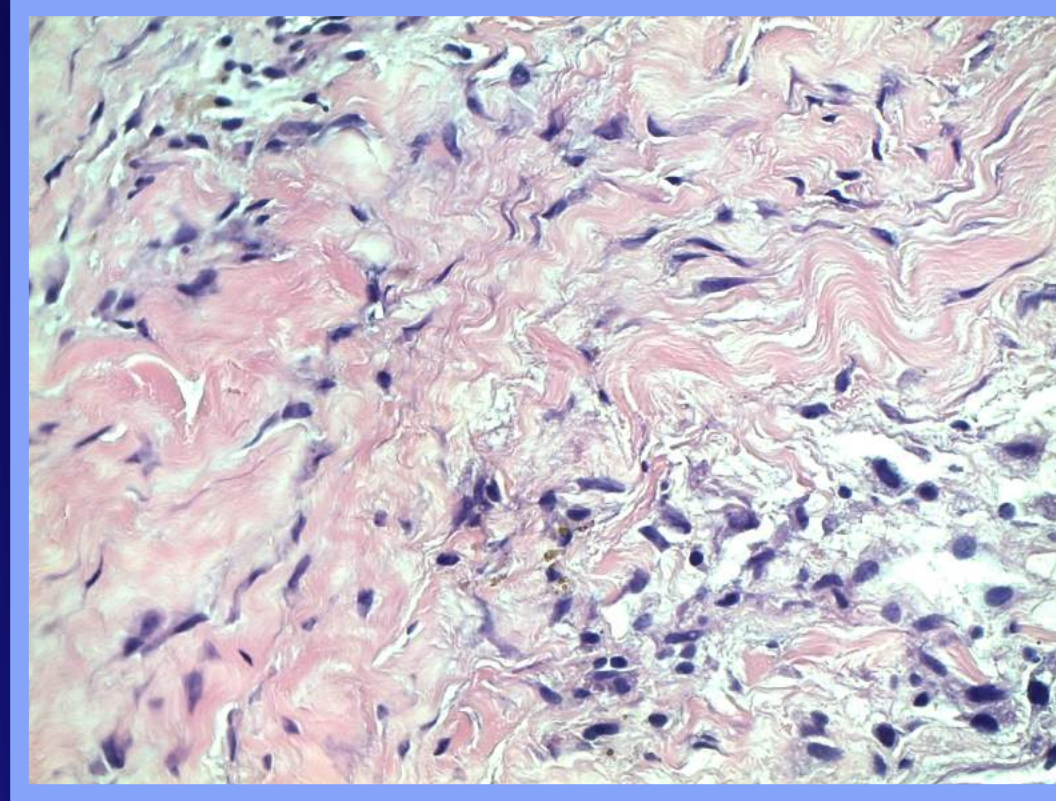
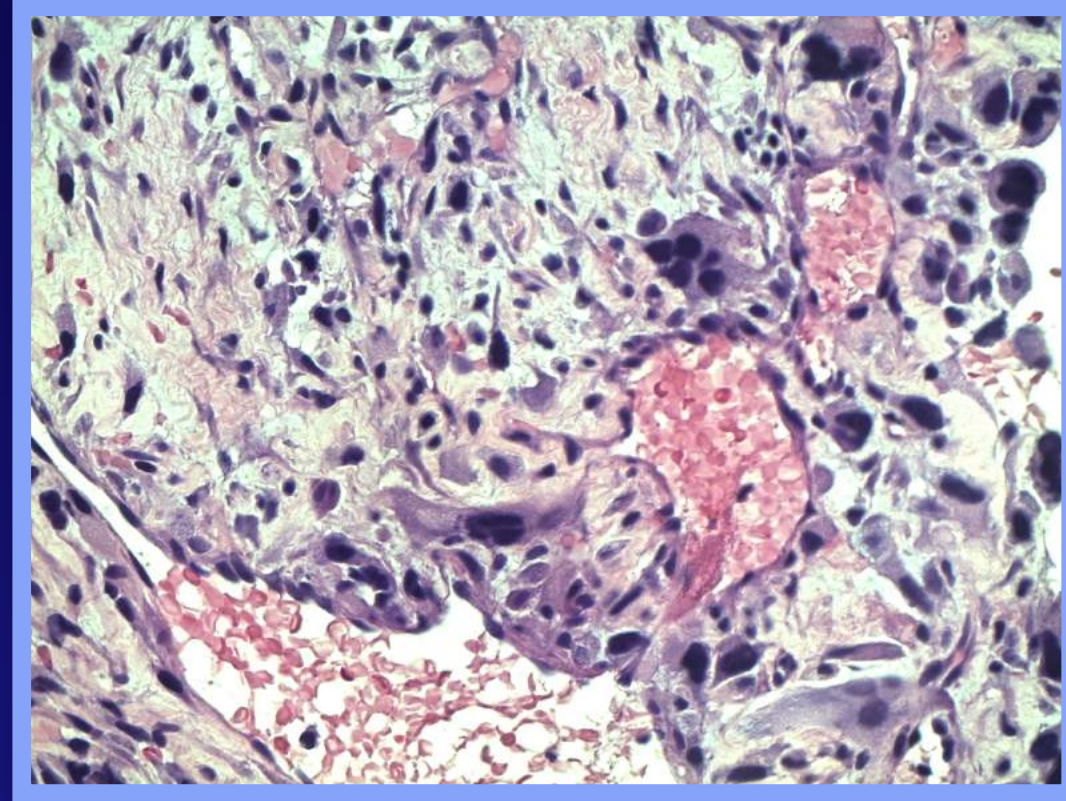
Ryoya



Ryoya is a 17 year-old male who developed osteosarcoma in his left leg. The patient was in constant pain when he was first examined.

Conventional Tx cut out the “cancer” and instituted chemo therapy. He developed a pseudomonas infection, which stopped the chemo Txs; four surgeries were performed to remove the infection and they had to replace the rod in his femur.

Ryoya



Quantum testing of the pathology slides revealed glyphosate, CMV, aluminum, mercury, and cadmium in the cancerous tissue.

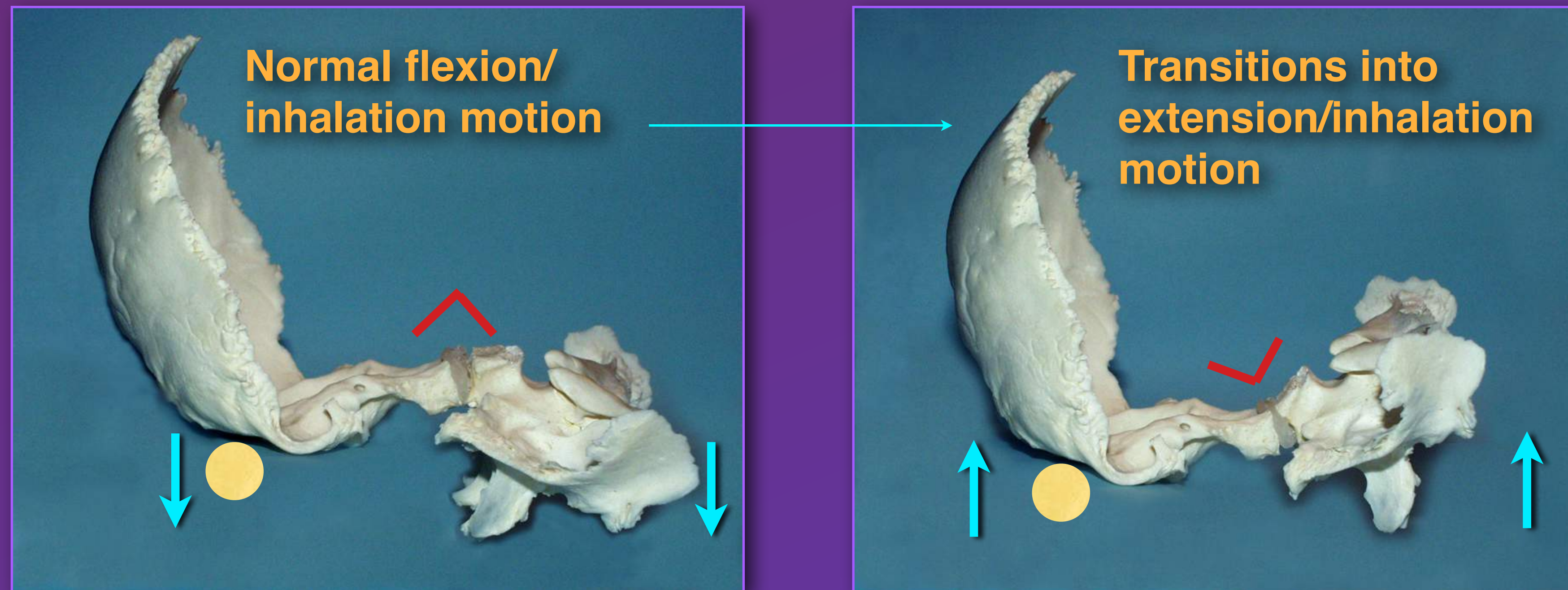
Six weeks after nutritional therapy was started his constant pain resolved. He was treated with the Theraphi System (scalar energy), laser, Rife frequencies, and nutritional therapy. Following removal of the glyphosate, all his allergies and pain resolved. He has been cancer free for over 4 years.

**Missing Link to
Resolving Post-
Concussion
Syndrome,
Migraines, and
Trigeminal
Neuralgia**

**Structural Basis for
Post-Concussion
that Conventional
Medicine Does't
Know Exists**

Fifth Cranial Indicator

Assessment of sphenobasilar motion in relationship to diaphragmatic breathing



Most therapists assume that the sphenobasilar motion (SBM) is in synchronization with diaphragmatic breathing. Trauma and iatrogenic procedures often reverse the process. A reversed SBM places tension on the dural membrane system.

Concussion



In 1995 Andy was at a hockey game. Two players crashed into a glass panel at rink side knocking it out of its support rails. The glass did not break but it hit Andy in the head. He was unable to work for 4.5 months. He suffered headaches (level 3 or higher) every day for the past 21.9 years. He could tell you when it was going to rain two days before. When it rained he would crawl into bed in a dark room because the pain was excruciating.

He has seen all the top specialists with no results. One cranial adjustment totally resolved his 21 + years of post-concussion symptoms.

Case Study #91

**How 20 Years of
Migraines Were
Resolved in One
Visit**

20 Years Migraine Headaches Resolved with one Cranial Adjustment

Cranial adjustment:
December 2015

Alcohol was a
trigger for her
migraines

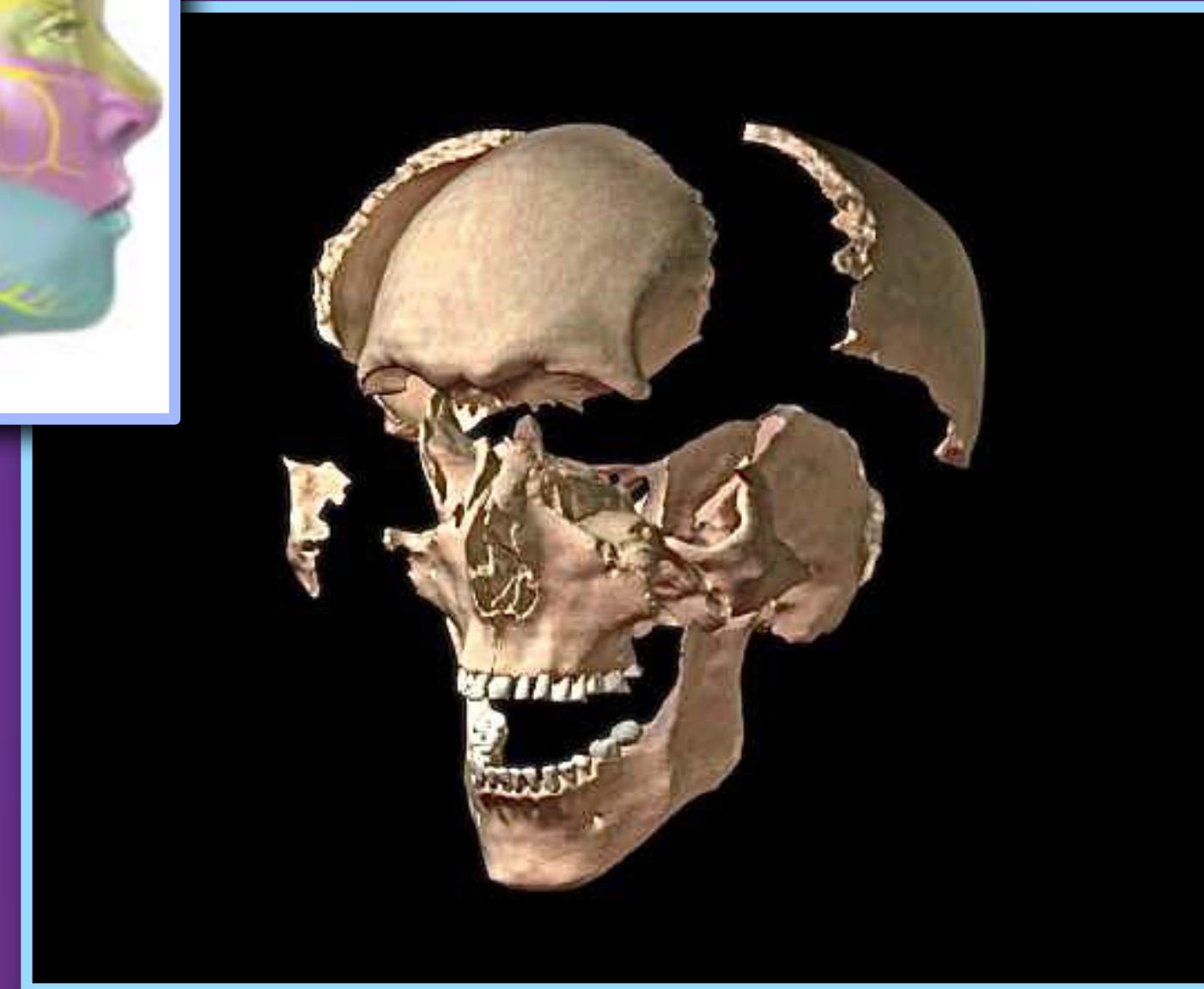
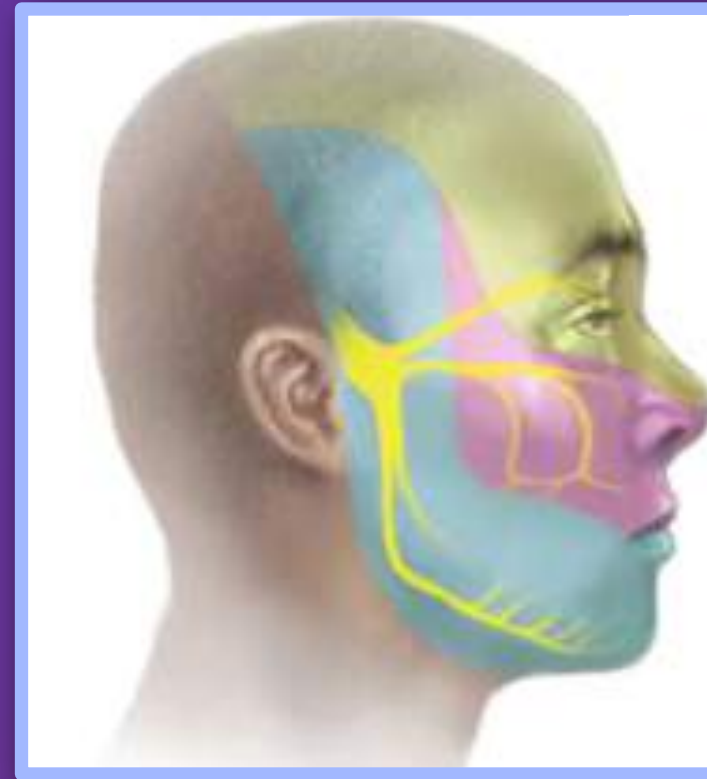
Patient has not had
a recurrence in her
migraines for over
seven years.

Case Study #59

Curing Trigeminal Neuralgia

CRANIAL MANIPULATION TO RESOLVE TRIGEMINAL NEURALGIA



When dentists insert fixed bridgework without monitoring the cranium, they potentially can torque the skull jamming sutures causing pain.

**Common
Denominator for
All Chronic Pain
Patients**

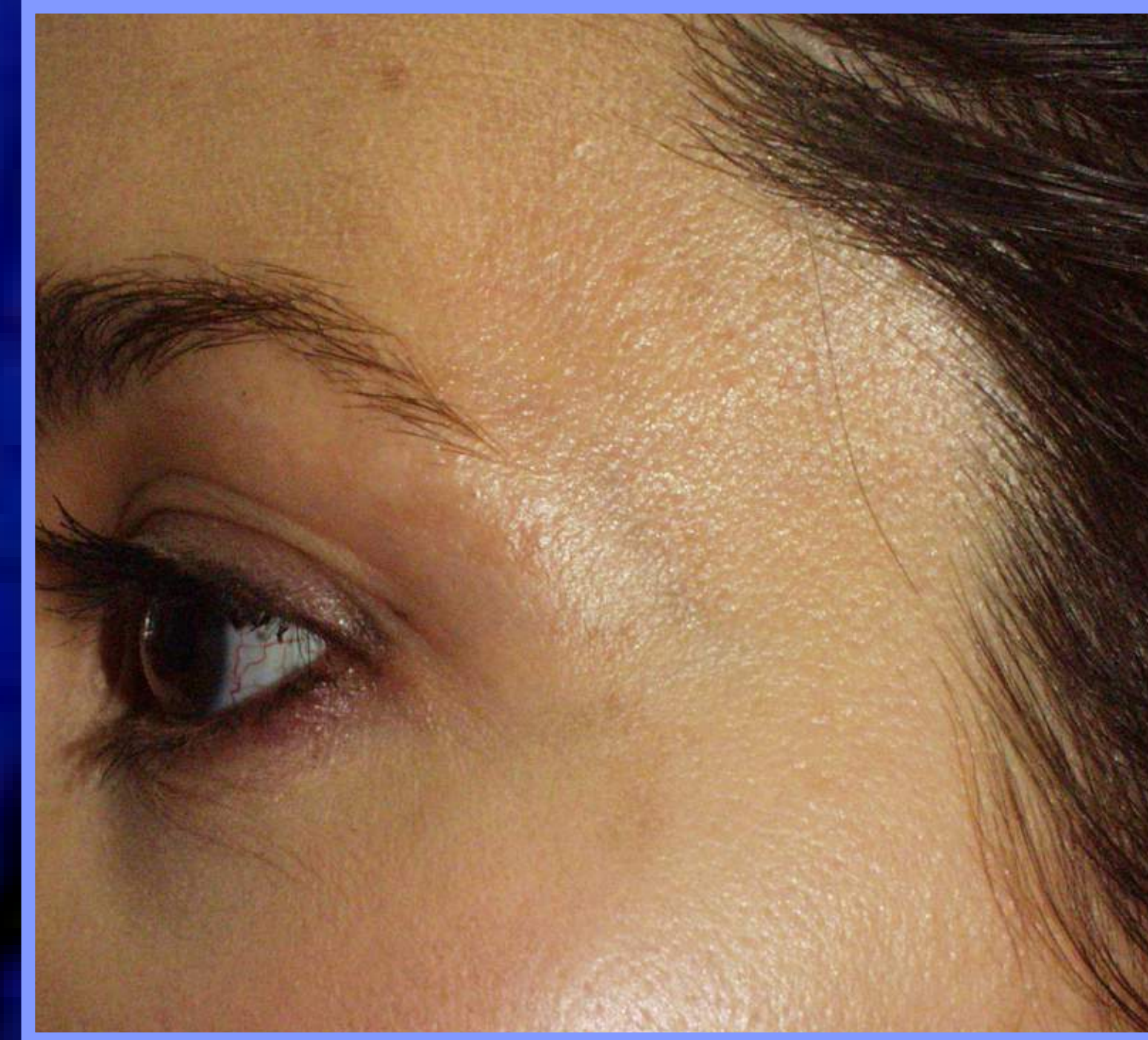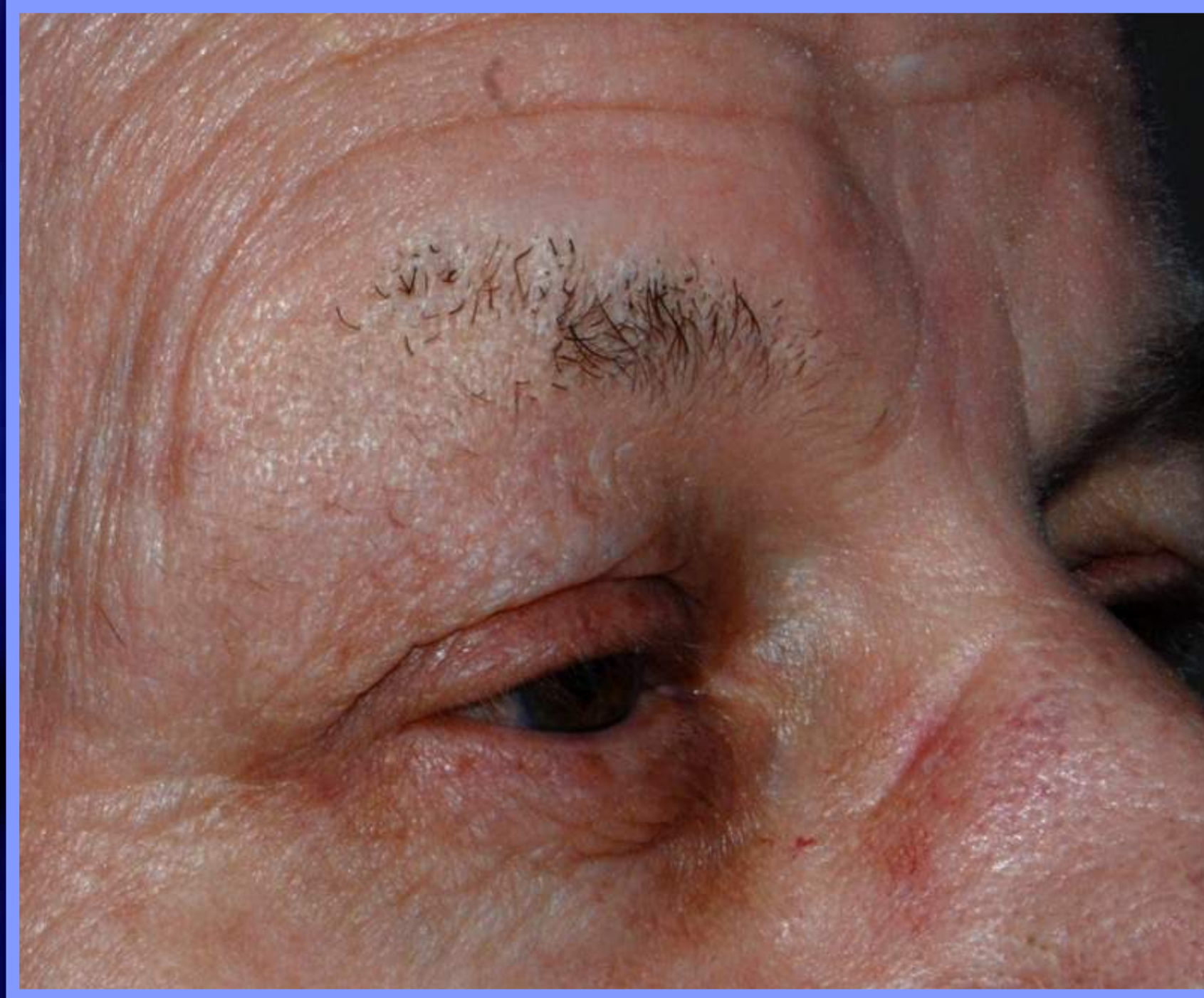Hypothyroidism

Over five million Americans have this common medical condition. In fact, as many as ten percent of women may have some degree of thyroid hormone deficiency. Hypothyroidism is more common than you would believe...and, millions of people are currently hypothyroid and don't know it!

Hypothyroidism

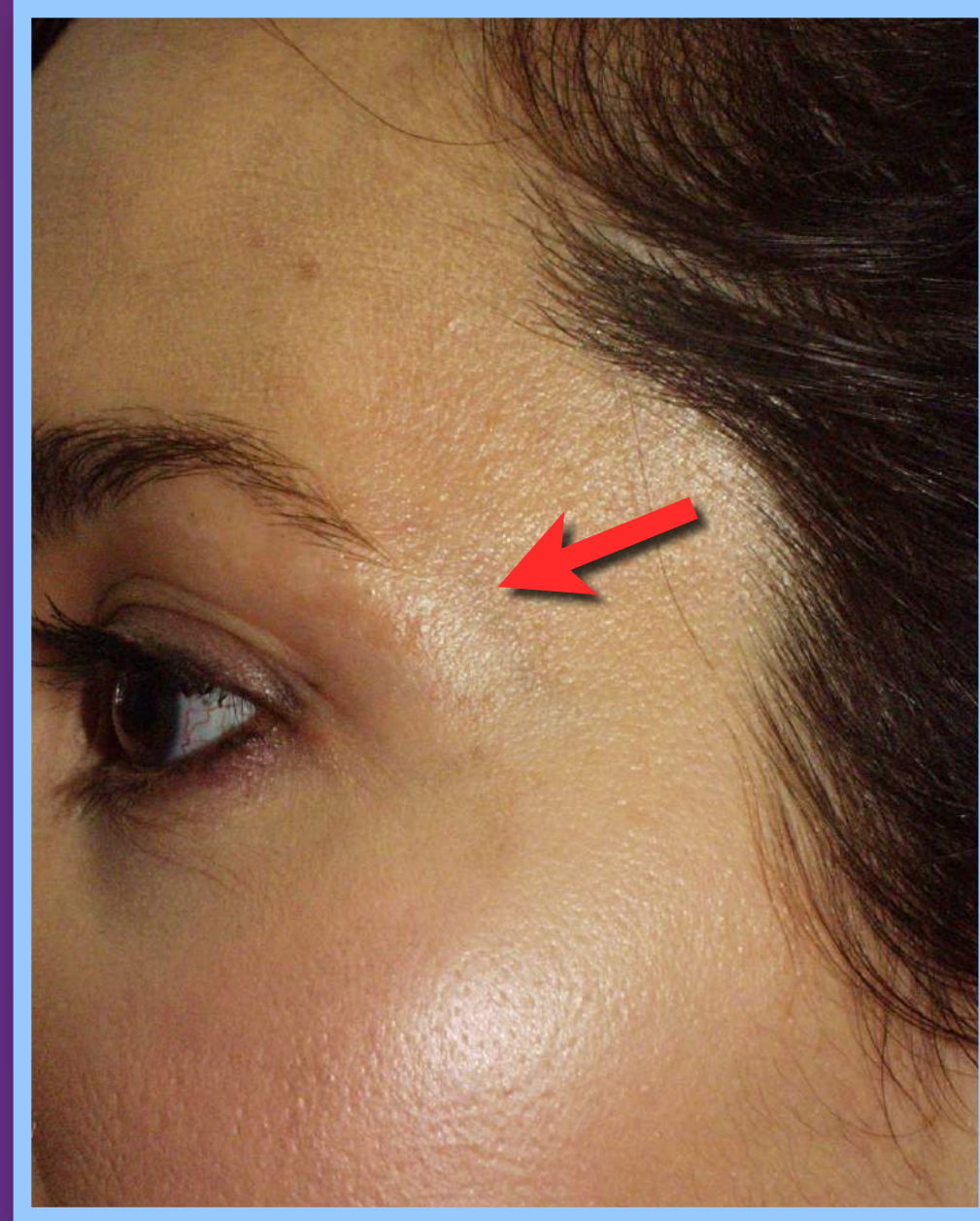The thyroid dictates the function of every cell in the body. When the metabolism decreases because of hypothyroidism, the metabolic wastes build up in all the cells. This is why fibromyalgia has diffuse pain patterns throughout out the body.

Clinical Signs of Hypothyroidism



Lateral third of eyebrow missing

Common Dental Issues



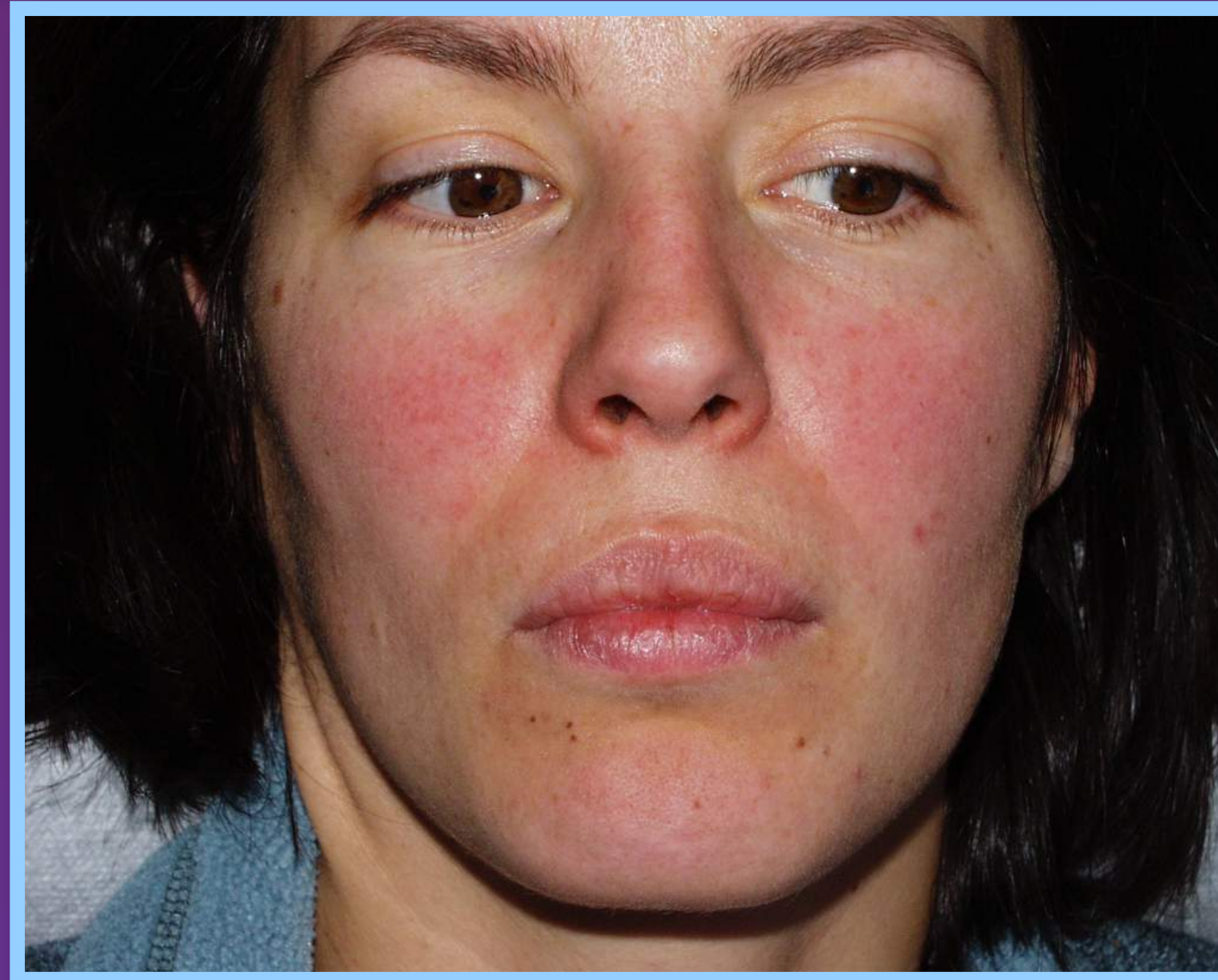A common clinical sign of hypothyroid patients is to be missing the lateral third of their eyebrow.

Queen Anne's sign

Hypothyroidism plays a major factor in treatment of chronic pain and TMD .

It is virtually impossible to resolve TMD symptoms (muscle spasm, diffuse pain, anxiety, depression, panic attacks, mental fog) without first resolving the under active thyroid!

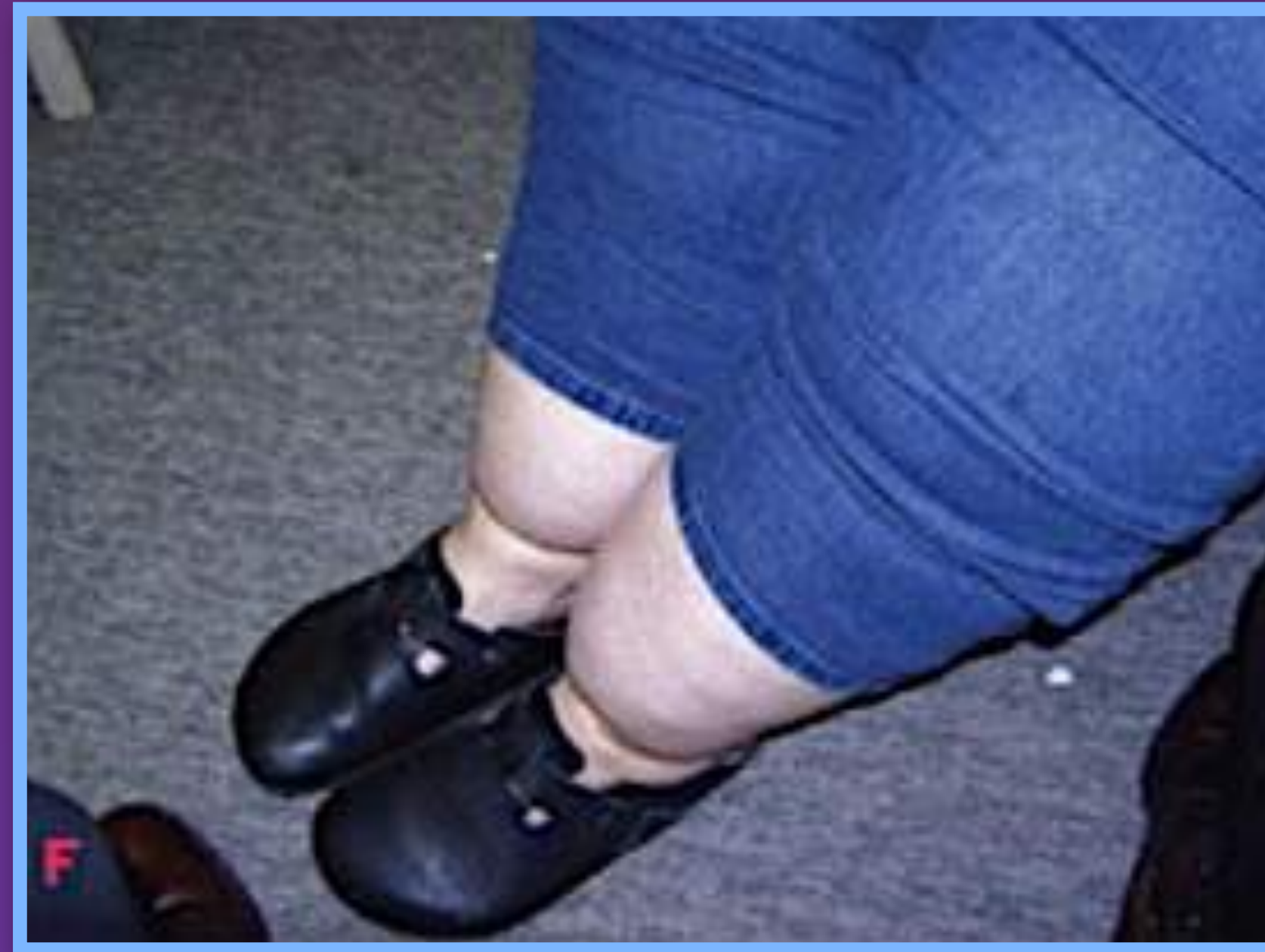Common Dental Issues



Another clinical sign of hypothyroidism is a butterfly “rash” present over the bridge of the nose. Additional symptoms include: brittle nails, poor digestion, tinnitus, dry skin, thinning of the hair, dizziness, allergies, skin rashes, acne, constipation, poor memory, enlarged tongue with scalloping, weight gain, slow speech, hoarseness, inability to concentrate, muscle aches, cold hands and feet, weak immune system.

Hypothyroidism

Clinical Signs

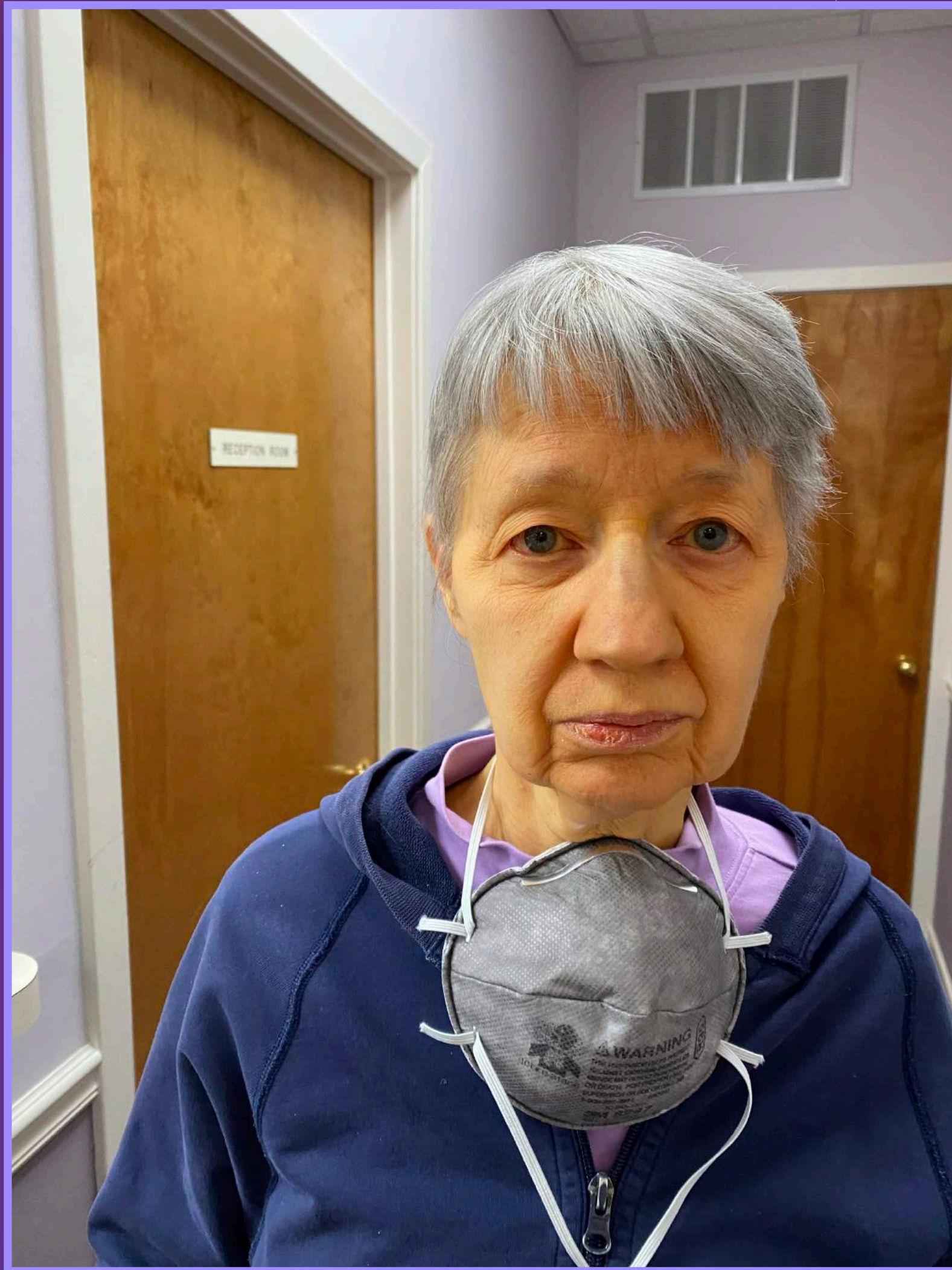

Thyroid hormone drives production of glycoaminoglycans, responsible for keeping water inside cells. In hypothyroidism, water tends to leak into extracellular spaces causing significant edema, easily recognized around the legs and ankles.

Hypothyroidism

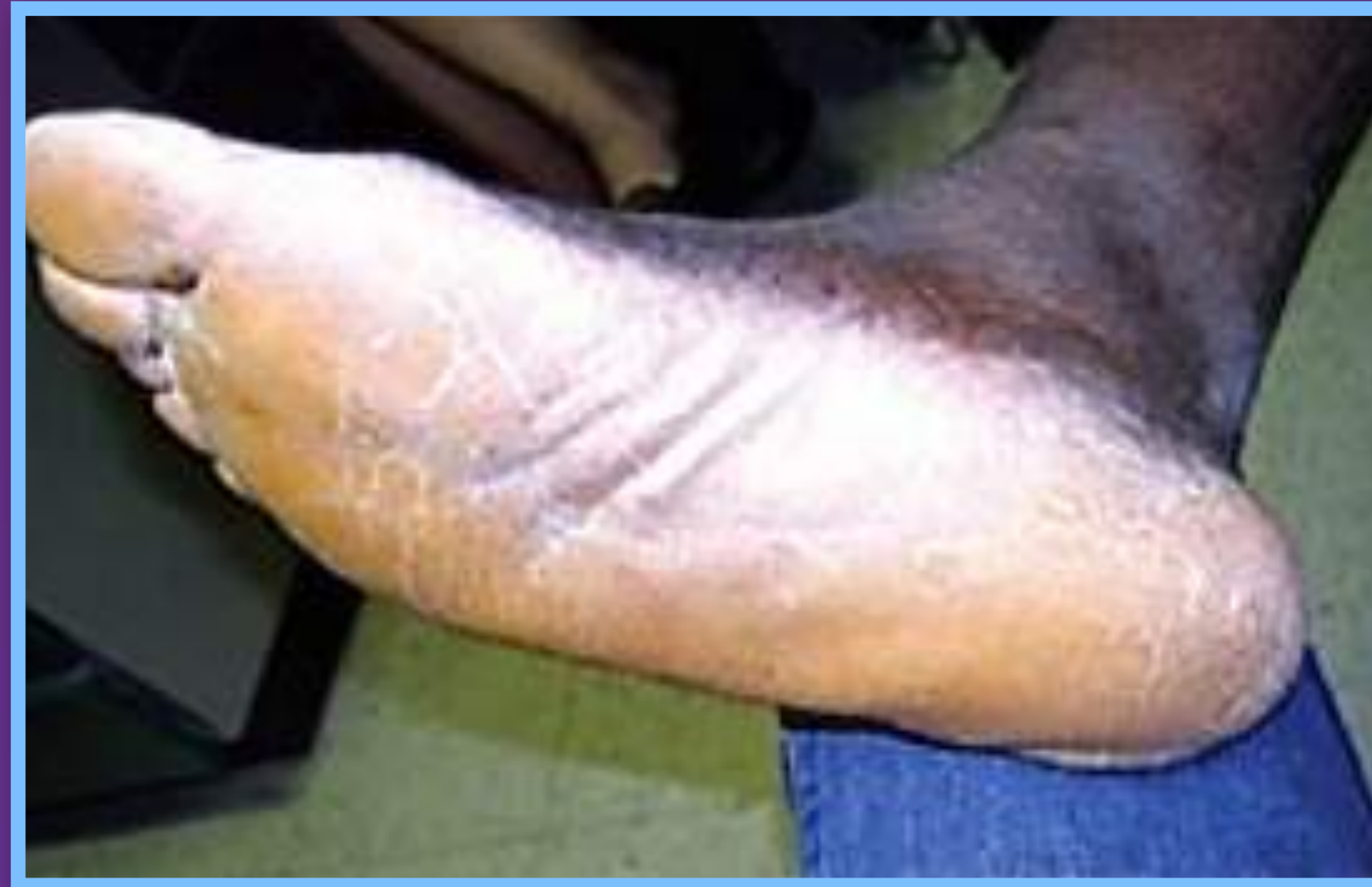Clinical Signs

Thyroid deficiency will manifest as an orange pigmentation due to a buildup of carotene in the skin. Conversion of beta carotene to vitamin A is dependent on thyroid hormone.



Hypothyroidism

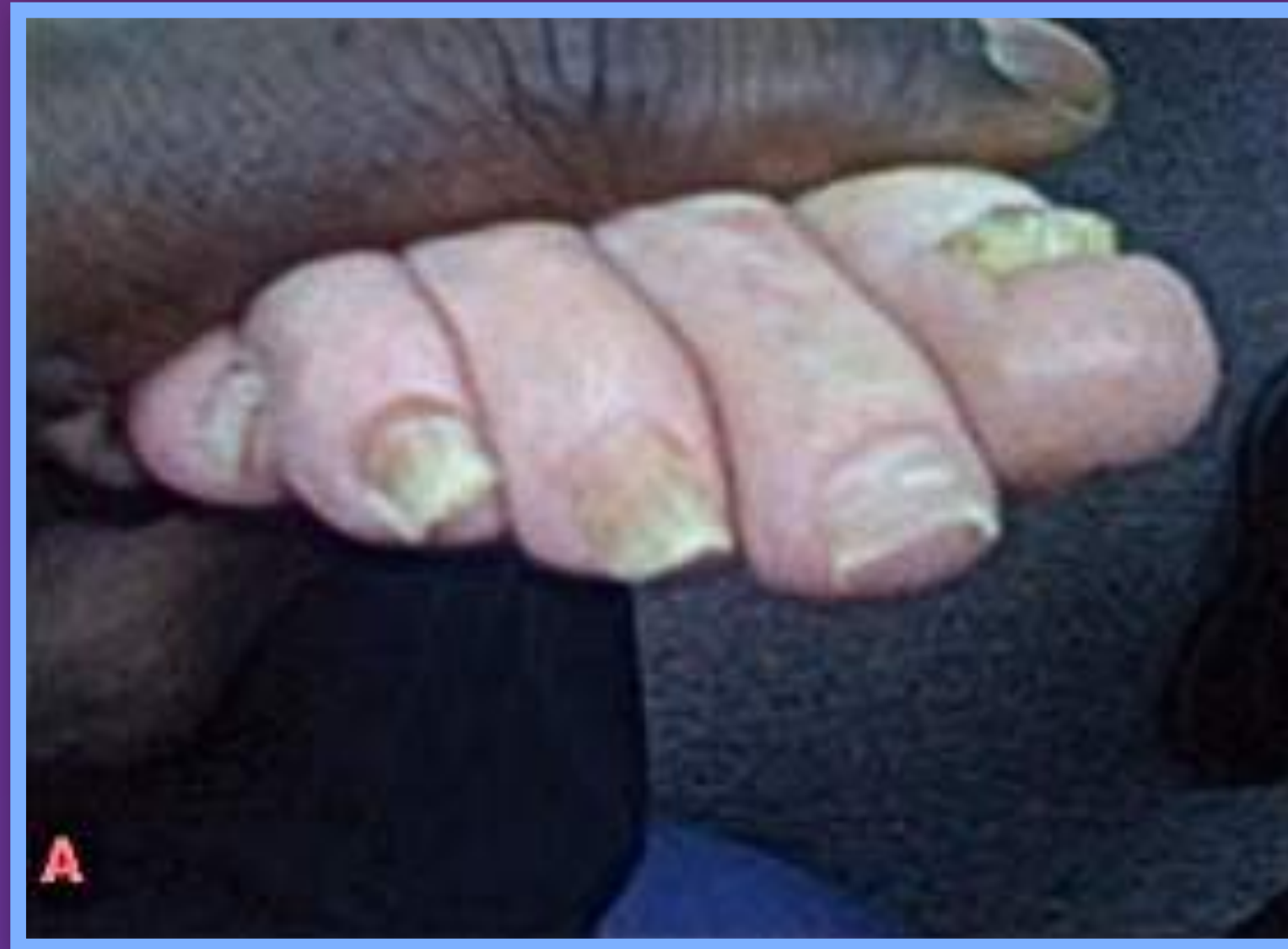Clinical Signs



Thyroid deficiency will manifest as a yellowish buildup of carotene in the skin of the palms and soles. Conversion of beta carotene to vitamin A is dependent on thyroid hormone.

Hypothyroidism

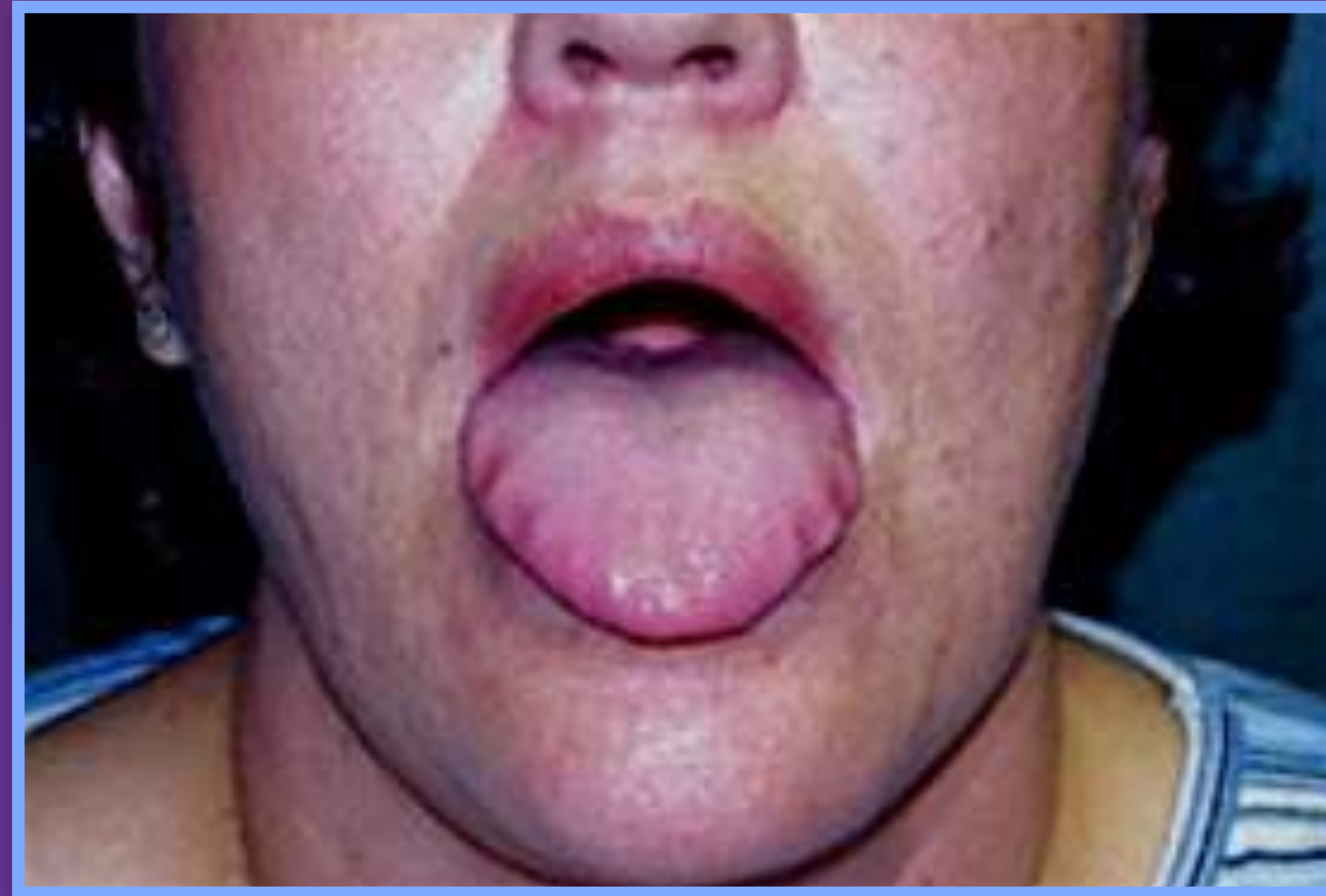Clinical Signs



Extensive fungal infection of the finger and toenails (onychomycosis) is often associated with hypothyroidism.

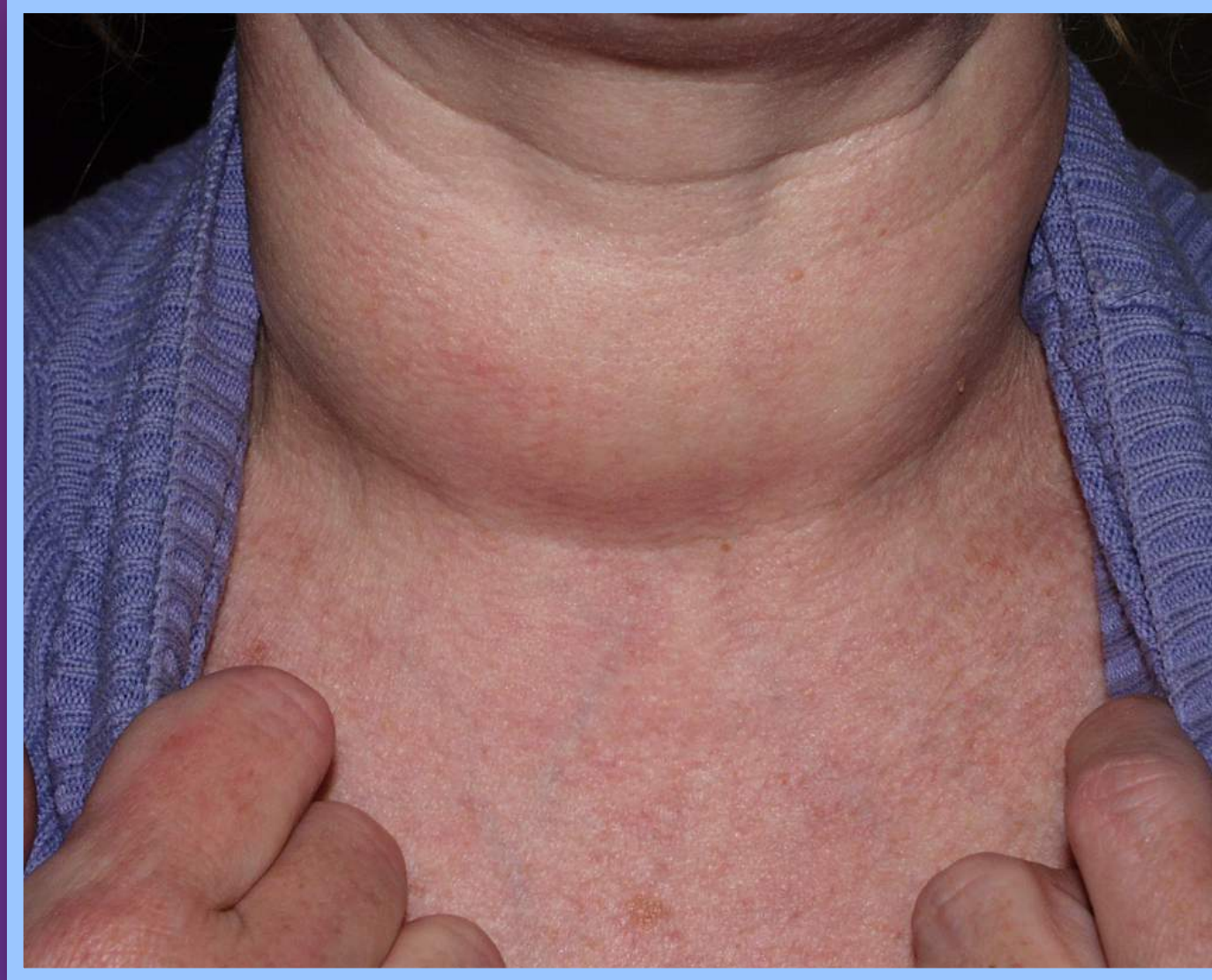Hypothyroidism

Clinical Signs



Scalloped Tongue

Common Dental Issues



Goiter: Tx - define whats in the thyroid and remove it. More effective to first detox. Often the thyroid starts functioning once it is cleaned out. If needed, nutritional support can be given: manganese, iron, selenium, iodine (Lugol's, kelp, Magnascent), desiccated thyroid T4 & T3. Do not recommend Synthroid or Armour (has corn as a filler).

Hypothyroidism

Common Symptoms

Fatigue	Hoarseness
Forgetfulness	Hair loss
Insomnia	Palpitations
Weight gain	Cold hands and feet
Constipation	Dry skin
Digestion problems	Infertility
Menstrual problems	Peeling nails
Mental fog	Muscle spasm
Swollen tissues	Trigger points
Dizziness	Depression/anxiety
Frequent colds	Lowered immune system

Hypothyroidism

Common Symptoms

Headaches	Loss of libido
Decreased sweating	Allergic disorders
Muscle and joint pain	Mood swings
Miscarriages	Slow speech
Decreased mental sharpness	Fluid retention
Skin pallor	Enlarged tongue/scaloping
Low blood pressure	Loss of hair: outer eyebrow
High cholesterol/triglycerides	Slow pulse rate
Cold intolerance	Tingling/numbness extremities
Goiter	Brittle nails

Hypothyroidism

Major Factors That Suppress Thyroid Activity

- **Drugs:** Prozac has three molecules of fluoride; Synthroid shuts down thyroid; birth control pills; steroids
- **Dental Infections:** Toxins migrate via lymphatics
- **Calcium:** Suppresses thyroid activity
- **Heavy Metals:** Nickel from jewelry, aluminum from underarm deodorant, cadmium from car exhaust and mercury from fillings.

Causative Factors for “Autoimmune Diseases”

Hashimoto's Disease Dental Connection

Lisa S.

22 year-old accountant
diagnosed with Hashimoto's
disease.

C.C. Severe fatigue, weight
gain, poor memory, insomnia

Medical Tx: Thyroid hormone.

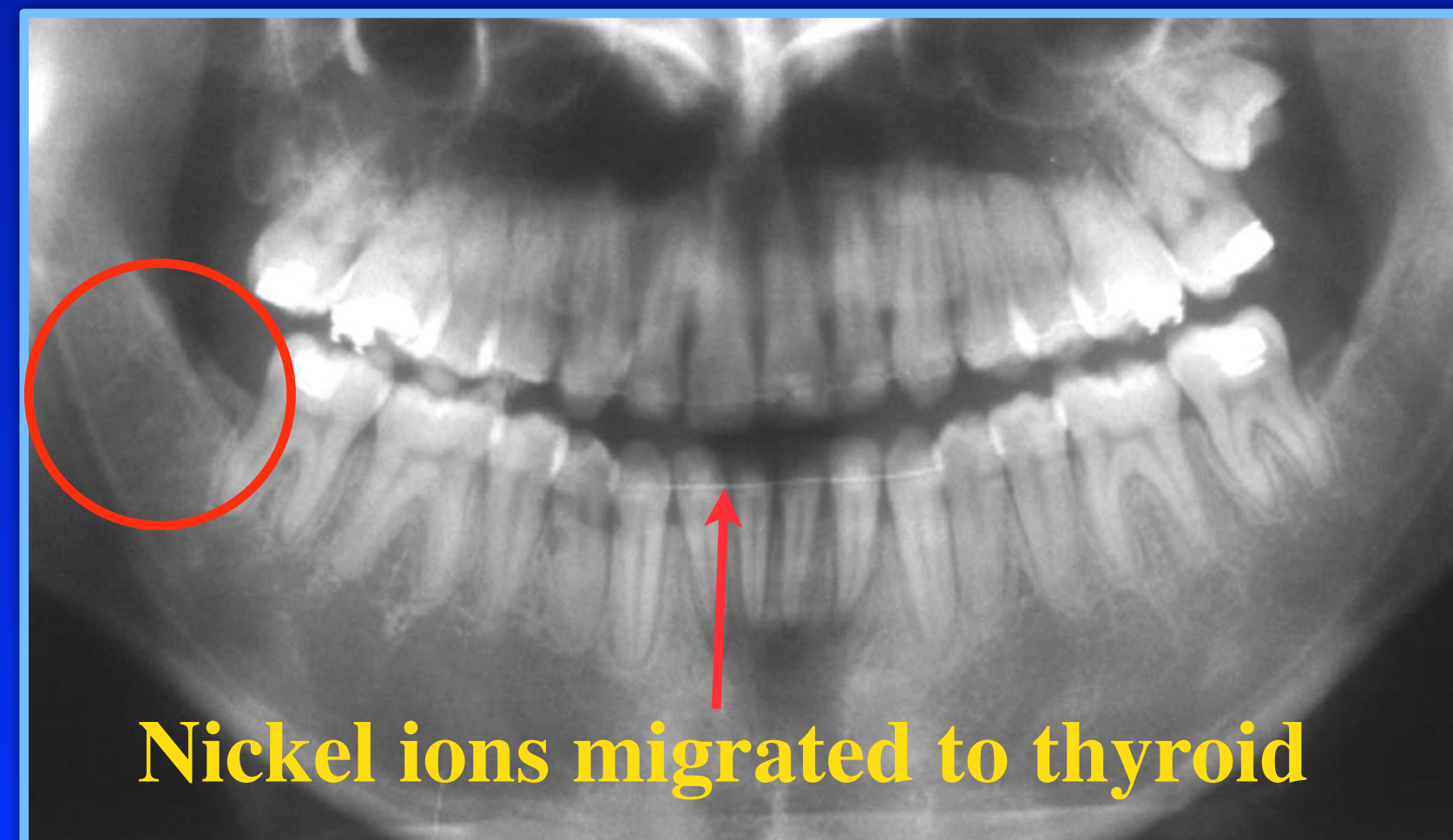
No change

Direct Resonance testing:

CMV and nickel toxicity in
thyroid.

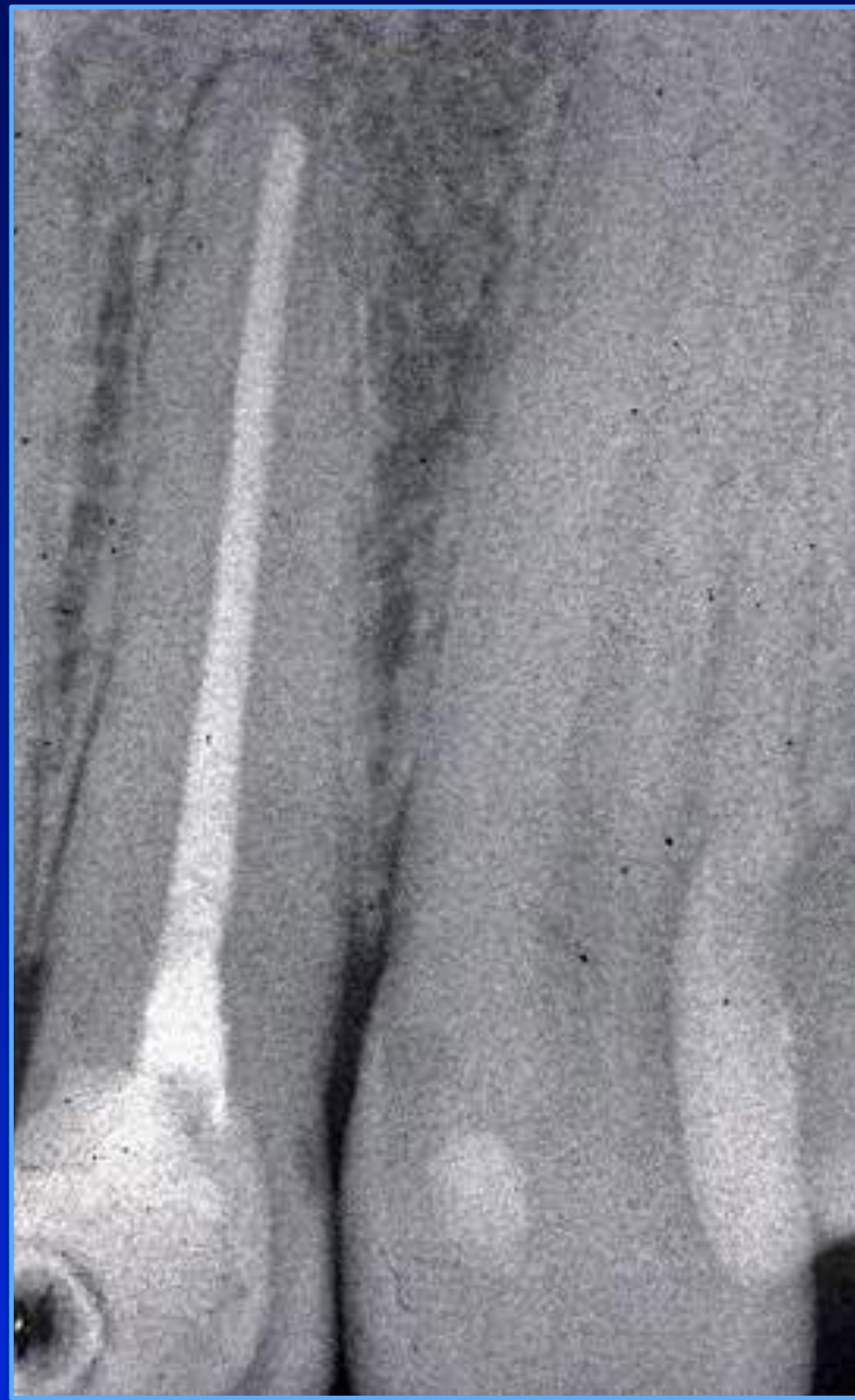1997 - Extraction of lower right third
molar resulted in an infection. CMV
migrated to thyroid.

Hashimoto's disease is classified as an auto-immune problem where the body attacks the thyroid. The primary symptoms are the same as an under active thyroid: tiredness, forget-fulness, depression, coarse dry skin, slow heartbeat, weight gain, insomnia constipation and intolerance to cold. According to traditional medicine there is no cure.



Dental Rheumatoid Arthritis Connection

1973



Root Canal at age 29

- Age 30 - First signs of rheumatoid arthritis: swollen knees appeared one year after root canal therapy performed in tooth #10.
- 1974-2004 -Patient placed on prednisone, methotrexate and Enbrel (yearly cost \$13,500) Enbrel is primarily used to block the tumor necrosis factor alpha (TNF alpha), which the body produces during the inflammatory response.
- 2004 - Direct Resonance testing: Dx Streptococcus viridans in root canal tooth. Three Txs with biofrequencies eliminated use of Enbrel and reduced swelling and pain by 98 percent.

Hypothyroidism

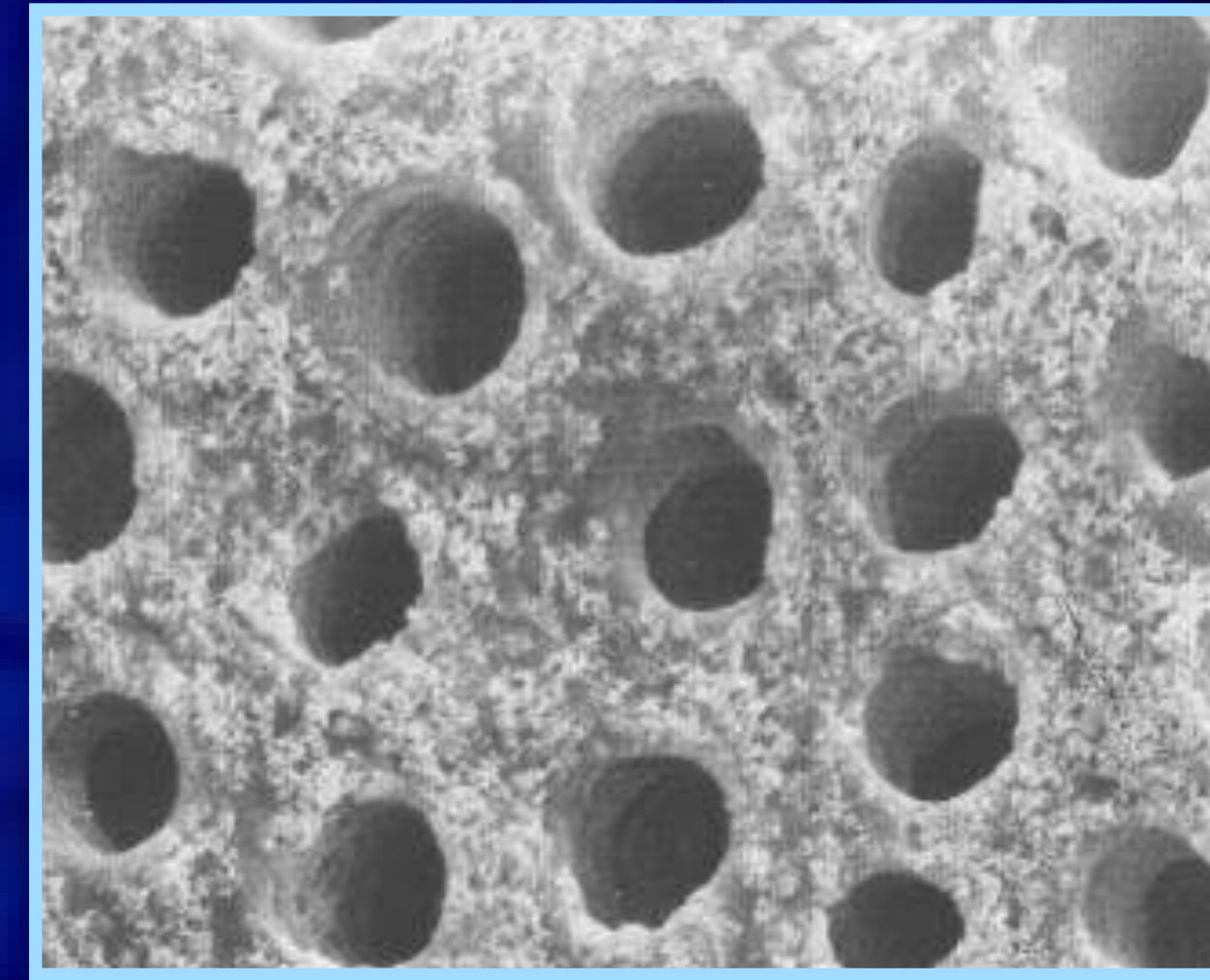
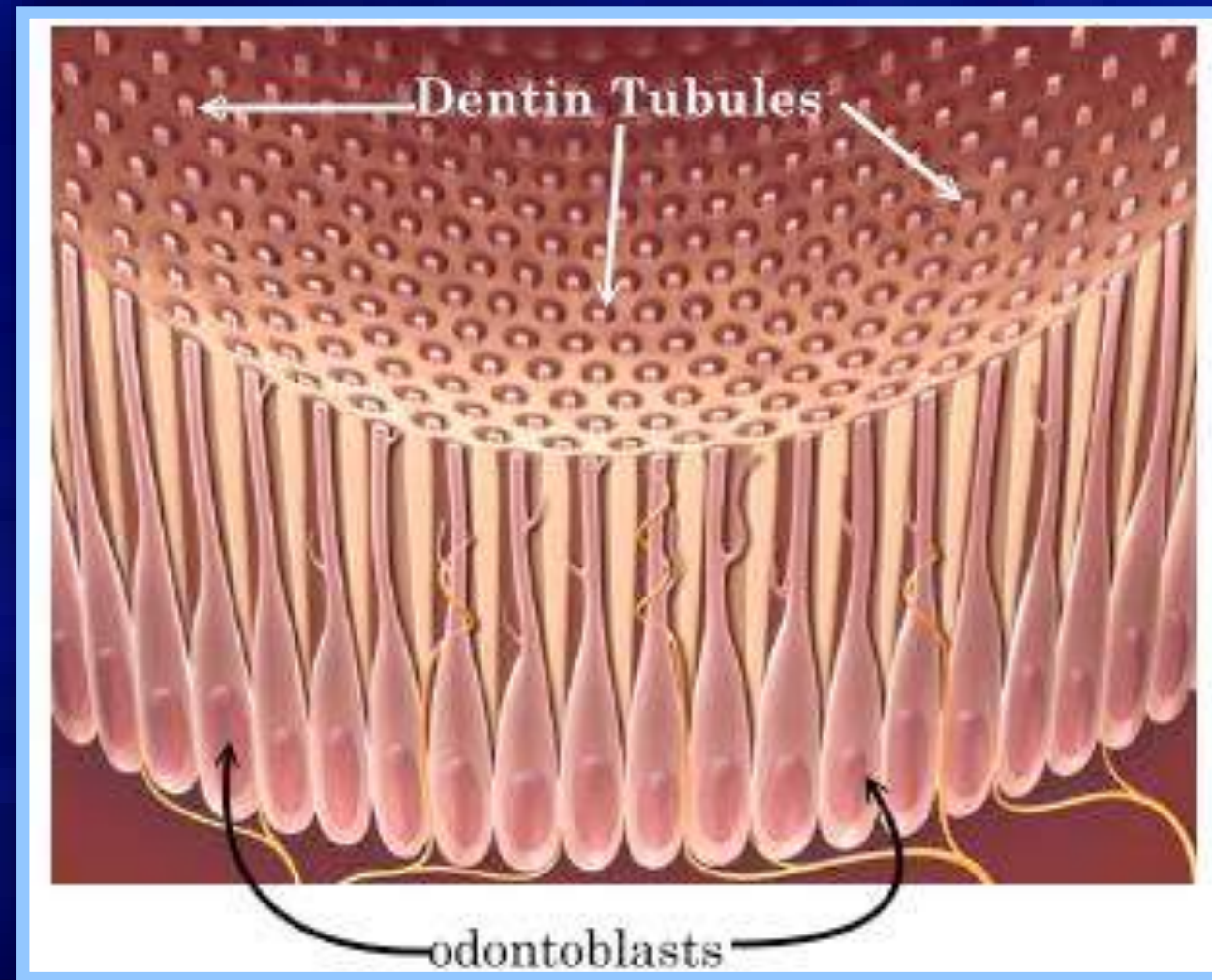
Major Contributory Factors

- **Chlorine:** present in public water
- **Bromine:** Used as a bleaching agent - flour products
- **Fluoride:** present in public water, tooth paste and drugs
- **Mercury:** primarily from fillings

The three halogens attach to the iodine receptor sites preventing iodine from being incorporated in thyroxine.

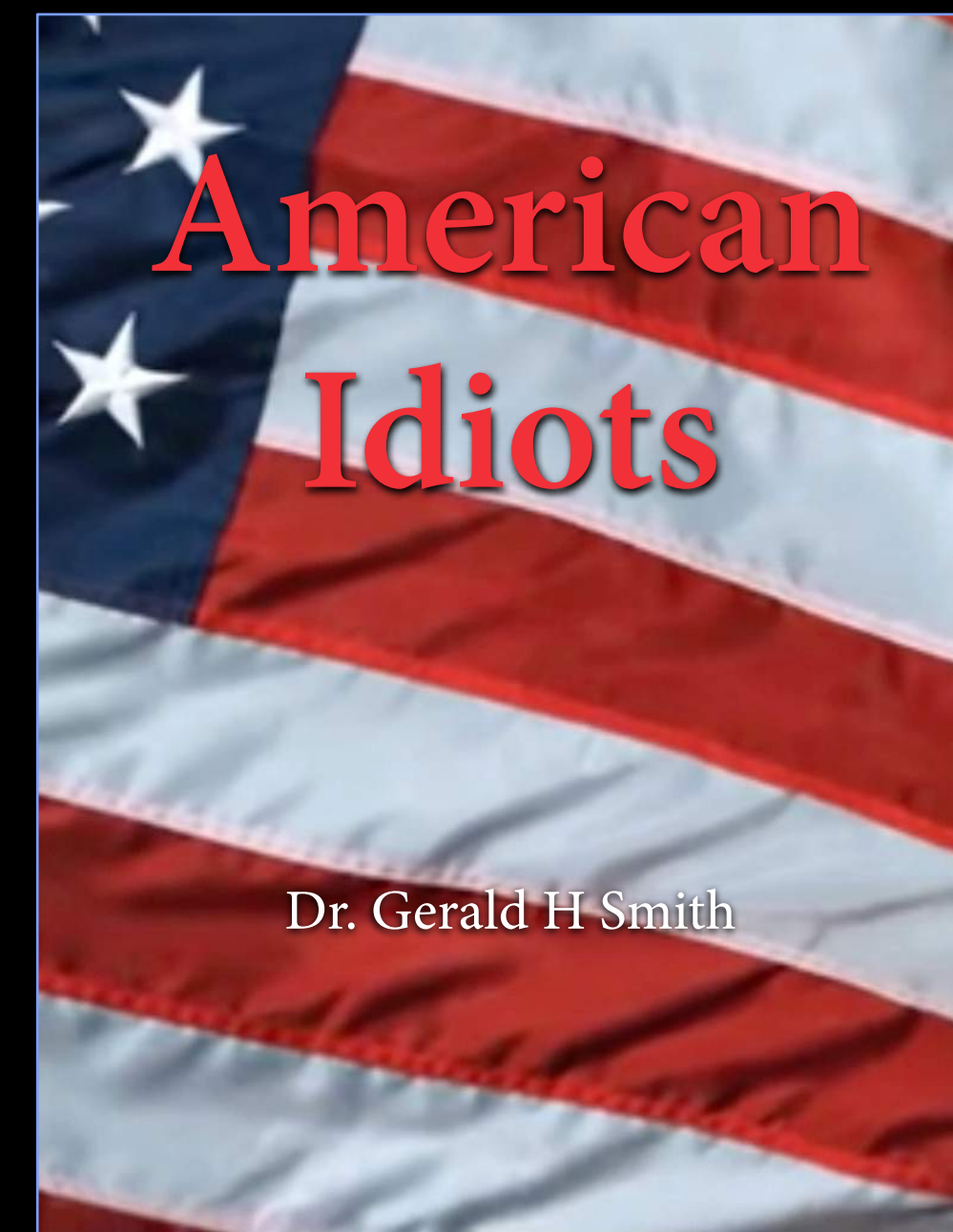
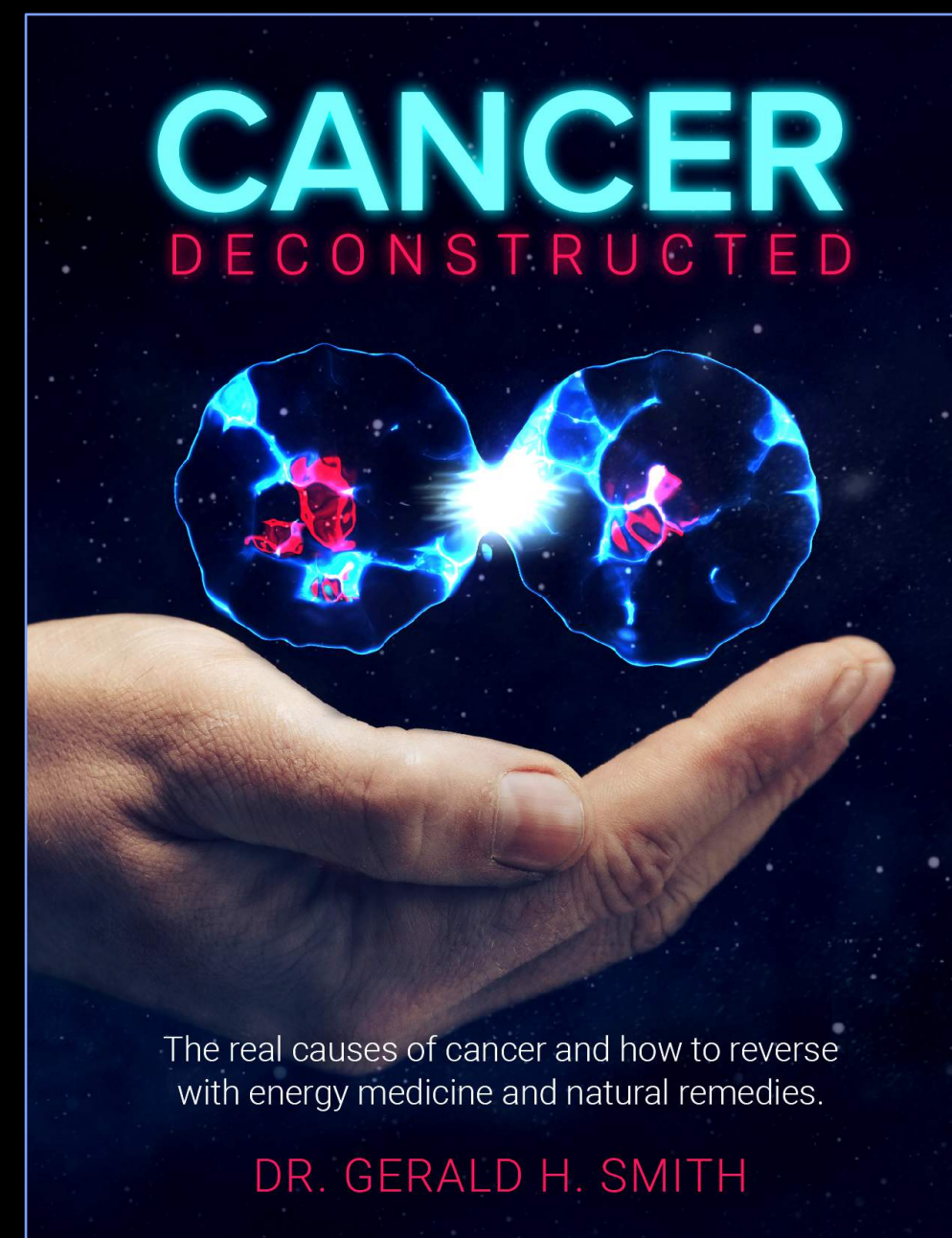
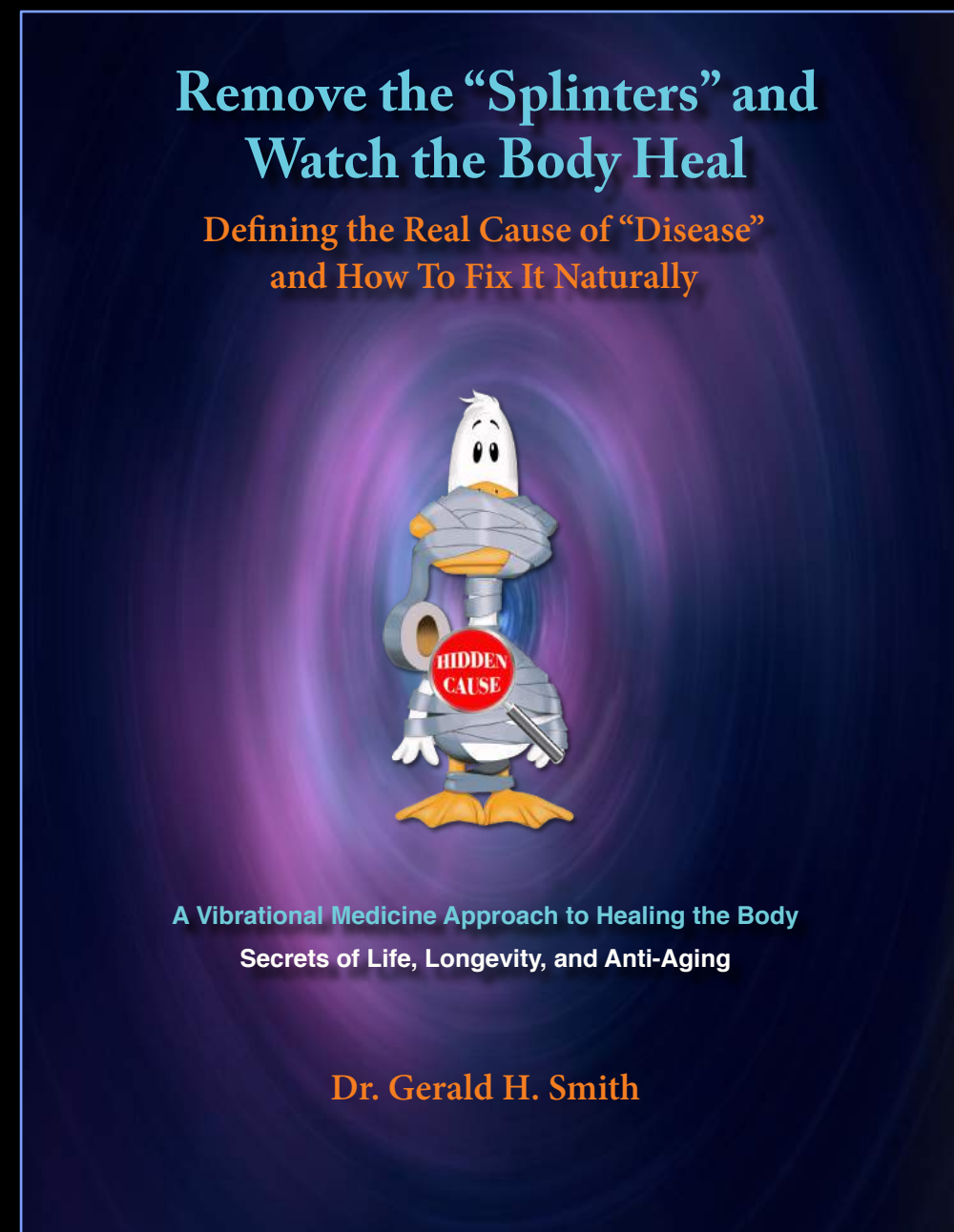
- **Hypoadrenia:** Underactive adrenals

Dental Connections



A molar tooth has approximately 3 miles of dentin tubules. Root canal teeth have been documented to have millions of bacteria with 400 different bacterial species. The released toxins function to suppress the immune system.

Three Best Books



Available in e-book: www.icnr.com

Free ten part docuseries on *Cancer Deconstructed*



IT IS BETTER TO WALK
ALONE, THAN WITH A
CROWD GOING IN THE
WRONG DIRECTION

HERMAN SIU

Visit My Websites

- www.icnr.com: 180+ case studies and many articles
- www.ghsdoc.live: library of video lectures, TV, radio, and podcast interviews

Please tune into our podcasts. Listings
for upcoming presentations on
ghsdoc.live