

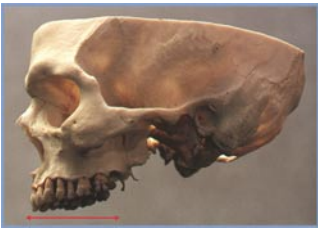Occlusal Cranial Balancing Technique

By Gerald H. Smith, DDS

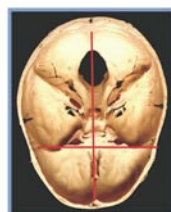
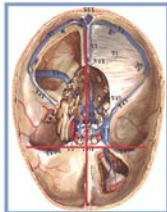
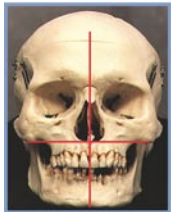
Published in the international journal, *Cranio*, vol. 14, No. 1 summer 2005

OCB is the acronym for Occlusal Cranial Balancing Technique. The OCB concept is based on the architectural principle of a level foundation. The principles of Occlusal Cranial Balancing are a monumental discovery and if applied will enhance total body function. The Occlusal Cranial Balancing Technique is based on two principal paradigms. The first focuses on the accepted orthodontic model that the maxillae, represents the anterior two-thirds of the cranial base and functions as the foundation of the human skull. The second focuses on the occlusion as being the self-correcting mechanism for re-balancing the cranial bones. The integration of these two paradigms is profound. Imbalances in either the maxillae and/or occlusal alignment has the potential for causing structural instability of the entire spine and pelvis complex, muscles, ligaments and fascial systems and functional imbalance of the central and autonomic nervous systems. The effect of a distorted maxillae coupled with a malocclusion provides answers to many of the age-old questions regarding the source of chronic pain and ill health.

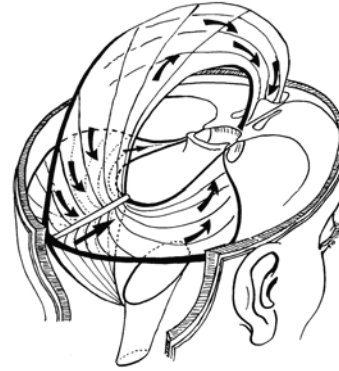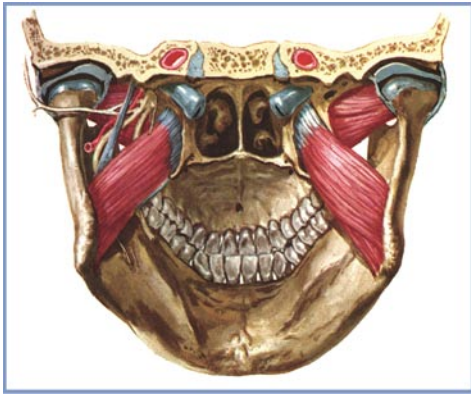
Mechanistic model. It is obvious to builders, carpenters, cabinet-makers and other skilled craftpersons that structures must rest on level foundations or be level to work properly. Also obvious is the idea that if structures like doors, floors, window frames or cabinets are not level they must be shimmed up. Since the maxillae represents the anterior two-thirds foundation of the human skull and the occlusion represents the self-correcting mechanism for balancing the cranium, dentists must now recognize and learn how to correct maxillary distortions and “shim” up the skull bones by correcting the bite.



Major DeJarnette, founder of the Sacral Occipital Technique, always referred to the maxillae as the anvil and the mandible as the hammer. DeJarnette stressed the concept that a level maxillae helped insure total structural stability via cranial and dural membrane balance. Conventional orthodontics recognize that the maxillae represents the anterior two-thirds of the cranial base but dentistry does not understand its impact on cranial and dural membrane stability. Since the dural membrane system extends to the sacrum, distortions from a dental origin have the potential of directly affecting spinal / pelvic alignment and all the associated structures (circulatory, lymphatic, muscular, ligamentous and fascial systems, endocrine and central and autonomic nervous systems).



The sutures between the skull bones represent expansion-contraction joints and function within a limited range to dissipate structural distress created by occlusal, spinal, pelvic and fascial distortions. Stresses beyond the adaptive functional range translate into dural membrane tension, which directly affects cranial nerves, cerebrospinal fluid transport, vascular flow and functions to hold cranial bones in distorted positions. Dural membrane tension goes beyond the cranial vault via its continuation through the foramen magnum and tenacious attachment to the upper three cervical vertebrae and slinky like reaction down the dural tube to the sacrum. This anatomic relationship provides the foundation for the importance of establishing a level maxillae (transversely and sagittaly) as the template to build the mandibular occlusion.



A level maxillae provides the foundation for balancing the pterygoid sling (internal and external pterygoid muscles) and realignment of the cranial bones. Humans swallow two to three times a minute during waking. Each time the teeth touch they provide the mechanical pressure to reset the maxillae. A delicate balance exists between each tooth contact and the alignment of cranial bones.

Each coupling of teeth represents a potential source for distorting the maxillary/cranial complex and the intra-cranial dural membrane system. The balance that exists is delicate and discrepancies of as little as a micron can make the difference between balance and chronic pain. The pain has its origin from sensory nerves of the three branches of the trigeminal nerve, which innervate the faux cerebri and upper surface of the tentorium cerebelli. Cervical nerves 2 and 3 innervate the surface below the horizontal membrane. Dural distortions provide the basis for chronic pain, structural imbalances down the entire spine to the sacrum and imbalances of the autonomic nervous system. Clinical experience confirms that the occlusion functions as the self-correcting mechanism for balancing the cranial bones and dura. It is for this reason that cranial distortions, malocclusion, toxic dental materials and dental pathology all play a major role in the etiology of approximately 70% of all medical problems.

Embryological Connection. The teeth develop from tissues that give rise to the nervous system. Specifically the maxillary and mandibular anterior teeth develop from the neural tube, which also gives rise to the sympathetic nervous system. The posterior teeth are derived from neural crest cells, which give rise to the parasympathetic nervous system. These embryological origins provide neurological-dental connections. This is the primary reason why distortions of teeth can potentially impact the function of tissues, muscles and organs that are innervated by the autonomic nervous system. In addition, the skull and pelvis are primarily innervated by the parasympathetic part of the autonomic nervous system, while the thoracic and lumbar vertebrae of the spine represent sympathetic innervations. The dural membrane system is an anatomic tube, which physically connects the skull bones with the upper cervical vertebrae and sacrum. Anatomical research in the early 1950's by the South African anatomist, Raymond A. Dart, disclosed a double helical arrangement of muscles from the base of the posterior occiput down to the pelvis. This slinky arrangement plus dural tube provides the cranio-sacral interrelationship with reciprocal and primary changes occurring at either end and in between.

Cranial Indicators. The key to diagnosing the interplay between malocclusion and cranial distortions is expedited by palpatory evaluation of the cranium by means of four basic indicators. This author has developed a diagnostic system utilizing four indicators as a means of assessing the skull 3-dimensionally.

1. Greater wing of the sphenoid.
2. Mastoids of the temporal bone.
3. Amplitude.
4. Sphenobasilar Symphysis (SBS)

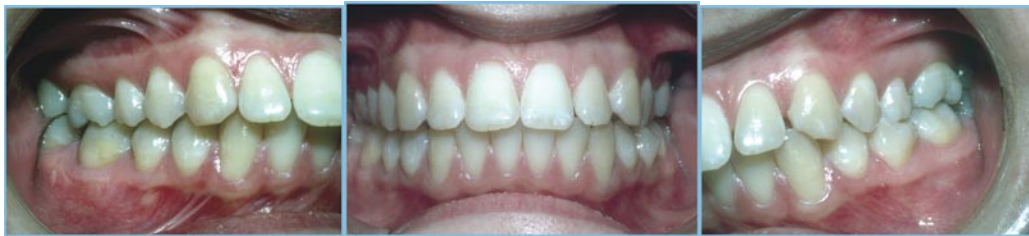The sphenoid is analyzed for roll, yaw, pitch and lateral strains. The mastoids are evaluated for roll and yaw distortions. The amplitude is examined for asymmetry and quality of motion, and fibrillation. The sphenobasilar is evaluated for pitch, roll and yaw distortions, lateral, vertical and inferior strain patterns or any combination. If the indicators are off, the intra-cranial membranes

are placed into a strain pattern. The indicators are an excellent universal guide for all phases of dental revision: adjusting restorations, crowns, bridges, ALF appliances, orthodontic appliances, occlusal modifications and even setting denture teeth and assessing their position in the wax try-in stage.

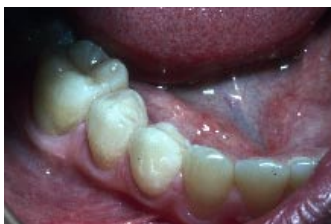Shimming Process. By establishing a baseline of the four cranial indicators, the clinician can compare the effect of maximum occlusal contact. In addition, by placing a strip(s) of 24-lb. paper between each coupling of teeth its effect on the cranial indicators can also be assessed. By determining the exact combination for balancing the cranium, shims can easily be placed by bonding on the appropriate tooth surfaces. The process is quick and often followed by immediate dramatic results.

Case 1. Fifteen years neck, shoulder and knee pain

K.B. was a 35-year-old female who suffered with right side neck, shoulder and knee pain for 15 years. All medical and chiropractic evaluations and treatment produce no change in symptoms. Evaluation using the Occlusal Cranial Balancing Technique revealed cranial distortions, which immediately corrected when paper shims were placed between the maxillary and mandibular first and second bicuspid teeth. Treatment consisted of placement of two occlusal resin shims the thickness of two sheets of paper on the mandibular bicuspids. The patient's right sided symptoms of neck, shoulder and knee pain of 15-year duration disappeared immediately. Treatment was performed in July 1996 with no recurrence of pain in nine years.



Most dentists would view this patient's occlusion as being within a normal functional range. The delicate occlusal cranial balance can only be assessed by palpation of the four cranial indicators. Omitting this diagnostic test allows occlusal cranial discrepancies to go undiagnosed and patient suffering to continue. Once diagnosed treatment is cost effective, non-invasive and easily performed.



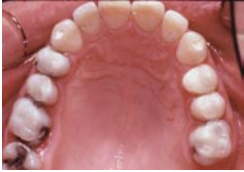Case 2. Six months low back pain

W.K. was in his early thirties when he was referred to our office in 1993. Walter presented with low back pain that prevented him from working for three months. Walter was treated with conventional medical therapy. He received three cortisone injections which served to mask the low back pain. The second cortisone injection lasted only six weeks and the third one had no effect at all. Walter was scheduled for low back surgery when his brother-in-law referred him to our office.

Dentally Walter presented with a malocclusion that involved a 1.5 millimeter loss of vertical height from the posterior teeth. This seemingly insignificant amount was the underlying cause of Walter's low back pain. A loss of vertical tooth height will cause compression of the spine. Such a "minor discrepancy" will be missed by 99.9% of all dentists. This functional relationship will also be missed by most orthopedic medical doctors, neurologists and even most chiropractors. The dental/low back connection involves several functional links: muscles that connect the upper cervical area and a dural tube which surrounds the brain and passes through the base of the skull and connects all the way down to the sacrum. This craniosacral

system works like a slinky. Distortions from above will influence structures below and visa versa. This functional connection has been observed and documented by this author as well as such researchers as Alred Fonder, DDS, Marjor Bertrand DeJarnnette, DC, Philip Green, DO and others.

Treatment must focus on rebalancing the skull bones in conjunction with providing vertical support to the teeth in the form of resin shims. The rational is based on the concept that the teeth are the self-correcting mechanism which resets the skull bones. Every time the teeth contact there is a rebalancing of the system. Restoration of the teeth requires a high skill level, which integrates cranial and dental concepts and the knowledge to balance both simultaneously. As a result of rebalancing Walter's craniosacral system via correcting the dental component the patient was able to return to work in ten days and has been pain free since 1993.



Occlusal shims must be judiciously placed to level the cranial bones as well as correct transverse and sagittal plane discrepancies. Restoration can only be accomplished by diagnosing the cranial distortions using palapatory skills. The four cranial indicators provide an efficient, accurate and cost effective system. At this point in time, there are no diagnostic radiographic techniques or computerized software that can make the evaluation.

Case 3. Ten years facial pain

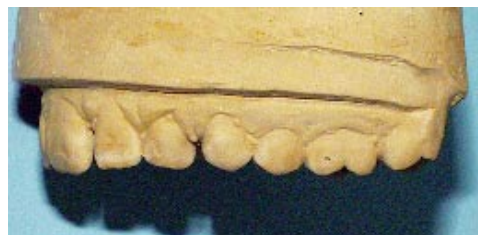Orthodontic treatment can be a double edge sword. Straightening the teeth represents one part of the restorative process. The other components of the mechanical equation are leveling the maxillary transverse and sagittal planes, restoring vertical support and balancing the cranial bones. In 1994 B.M., a seventeen-year old female patient, had completed orthodontic treatment. Although her teeth appeared straight, she was left with symptoms not present prior to the orthodontic treatment:

1. Constant excruciating facial pain requiring hot packs to alleviate spasm in order to fall asleep.
2. Difficulty talking.
3. Neck and shoulder pain.
4. TMJ pain.
5. Constant headaches.
6. Inability to sleep through the night because of the pain.
7. Fatigue.

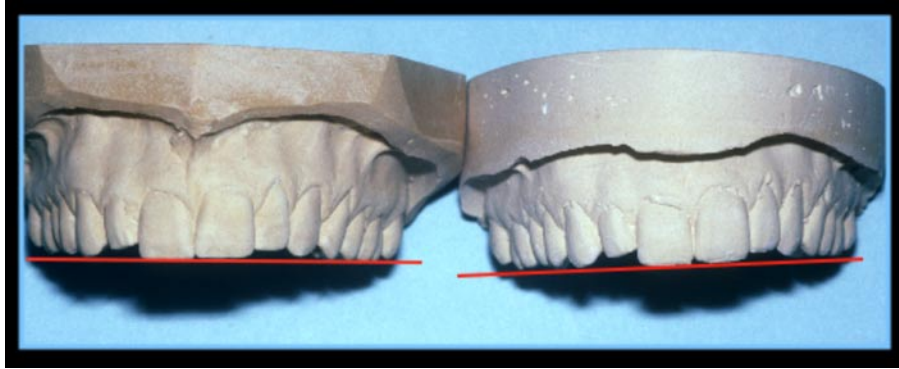
The patient had been evaluated by fifty doctors (medical and dental) during the ten-year period following the orthodontic treatment.

Pre-Treatment evaluation

The planes of the maxillae were distorted by orthodontic treatment. The transverse plane was canted high on the left and the sagittal plane was concave. The vertical plane was not corrected and the maxillae and dental arches were compressed.



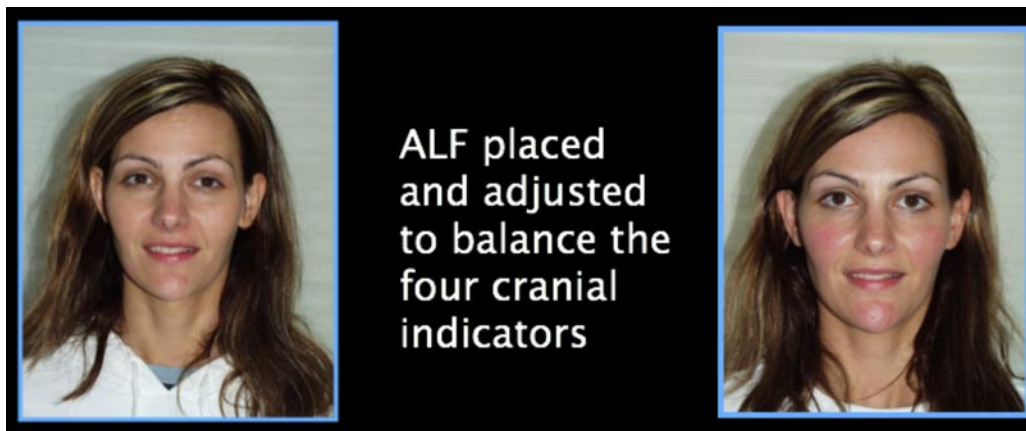Concave sagittal plane created by depression of first and second bicuspid teeth.



Post-Treatment evaluation

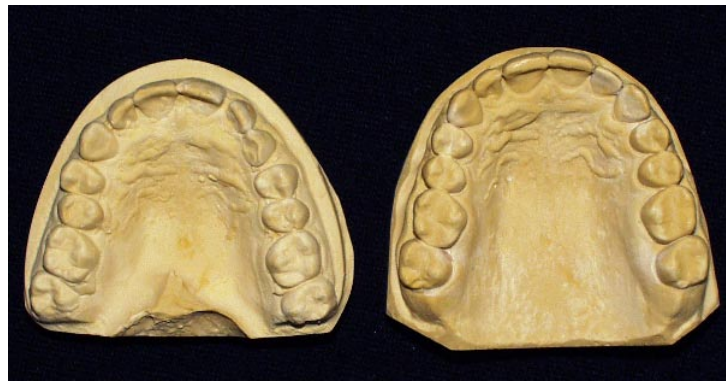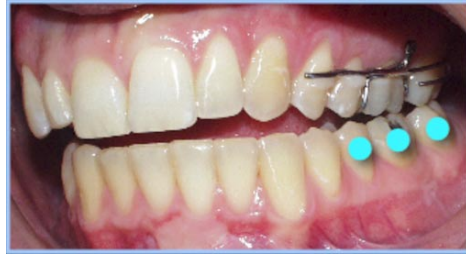Post-treatment leveled the transverse plane and corrected the concave left sagittal plane. The vertical was restored the dental arches expanded and the cranial indicators balanced.

The process of shimming can be accomplished with resin overlays or correcting the three-dimensional planes and teeth alignment. In this case treatment utilized the ALF appliance to correct the cranial faults and canted high transverse plane. Correcting the maxillae or foundation of the skull must be the first step in all orthopedic/orthodontic treatment plans. Aligning the teeth at the correct planes and vertical height establishes the self-correcting mechanism of balancing the skull bones. Within 24-hours of inserting the maxillary ALF appliance and adjusting it to correct the cranial faults, the patient experienced a dramatic reduction in facial pain. The cranial sutures allow rapid realignment of the cranial bones, which is witnessed by the dramatic change in the patient's facial anatomy.



Within 24-hours of inserting the maxillary ALF appliance and adjusting it to correct the cranial faults, the patient experienced a dramatic reduction in facial pain.

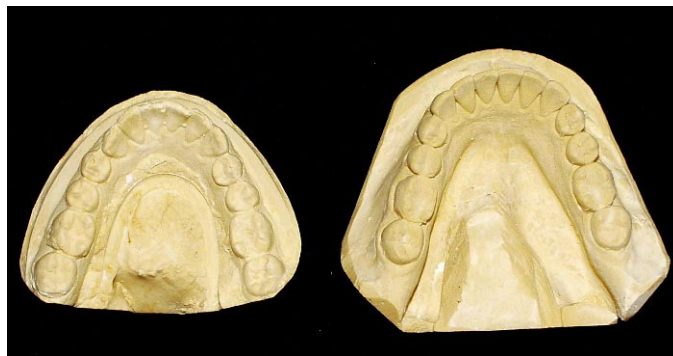The ALF appliance was designed to lower the high left cant of the maxillae and the orthodontic brackets were placed high on the left mandibular side to depress the extruded lower teeth and correct the transverse plane.



Pre-Treatment

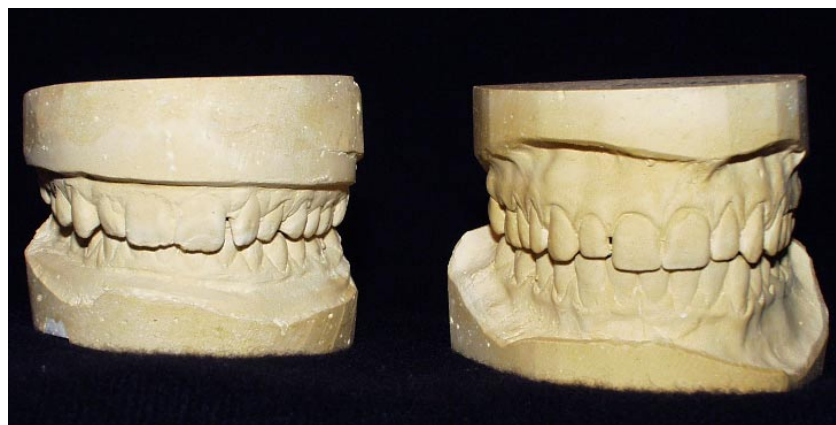Post-Treatment

The maxillary and mandibular dental arches were expanded, leveled and vertically corrected with ALF appliances and fixed orthodontics.



Pre-Treatment

Post-Treatment

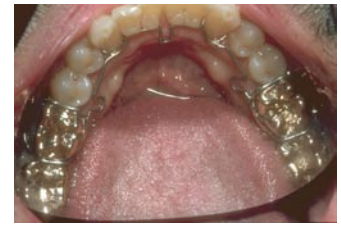
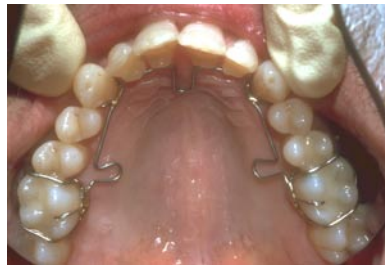
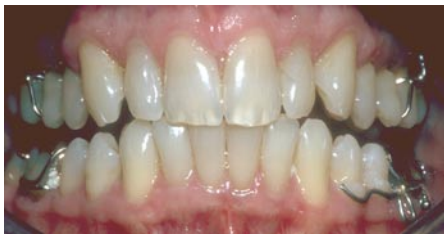Pre-Treatment

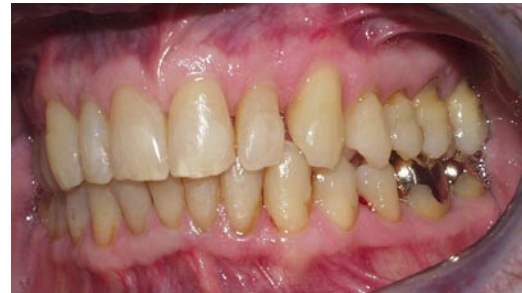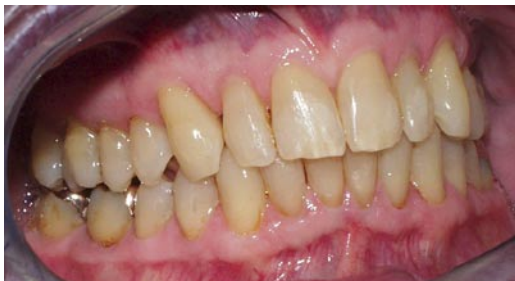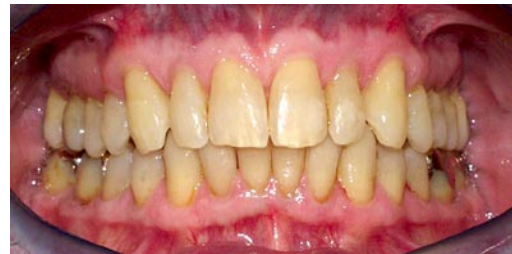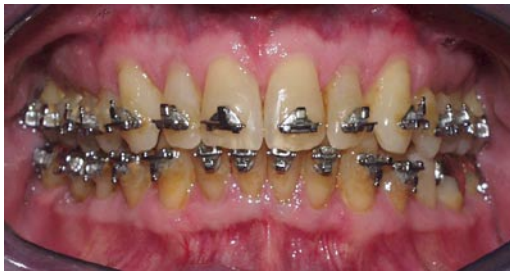Post-Treatment

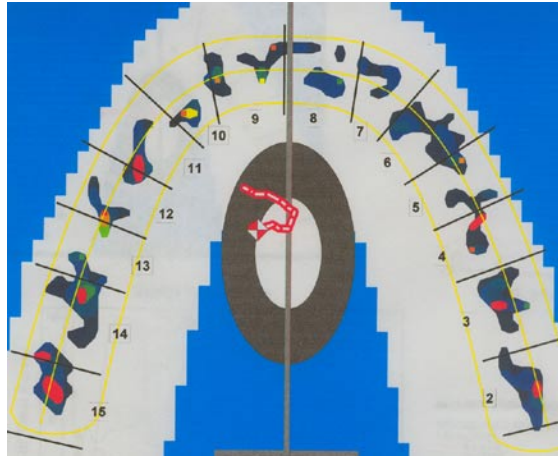
Case 4. Chronic head and neck pain

Michael M. is a dentist who wore a mandibular orthotic for years. The vertical support provided partial relief of the chief symptoms but did not totally resolve the pain. Although the orthopedic appliance achieved its goal of relaxing the masticatory muscles, the patient had no posterior tooth contact. The challenge was to conservatively restore the posterior occlusion and balance the dental-cranial-cervical complex. The mandibular arch had bilateral gold overlay crowns on the first and second molars. The objective was to bring all the posterior teeth into occlusion without having to replace the existing restorations. Treatment involved use of ALF appliances to free-up the pre-maxilla, correct other cranial distortions and expand the arches and finalize the case with fixed orthodontic brackets to erupt and align the posterior teeth. Key throughout treatment was monitoring the cranial indicators to guide correcting the cranial base and establishing final occlusal contacts. Once the foundation, maxillae, was corrected the teeth could then be erupted to stabilize the cranium. In this particular case, the natural occlusion was manipulated via orthopedics/orthodontics to “shim” the cranium. A combined dental and osteopathic team approach was used to totally resolve the pain.

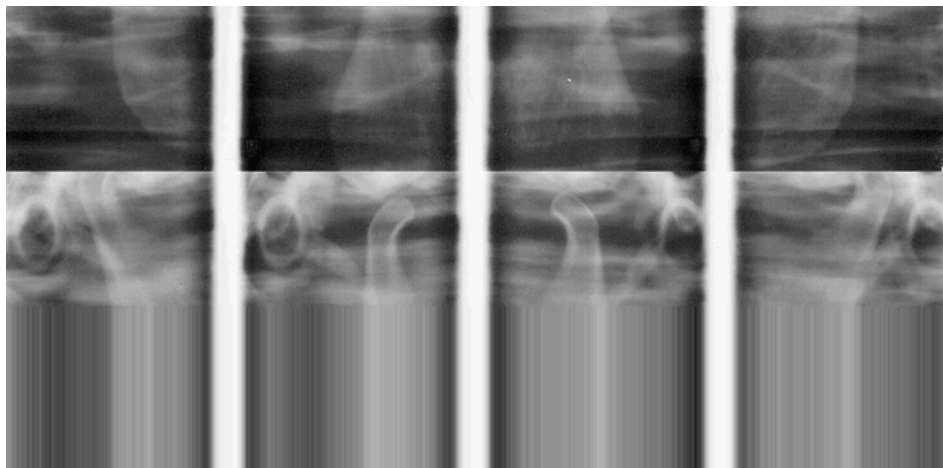
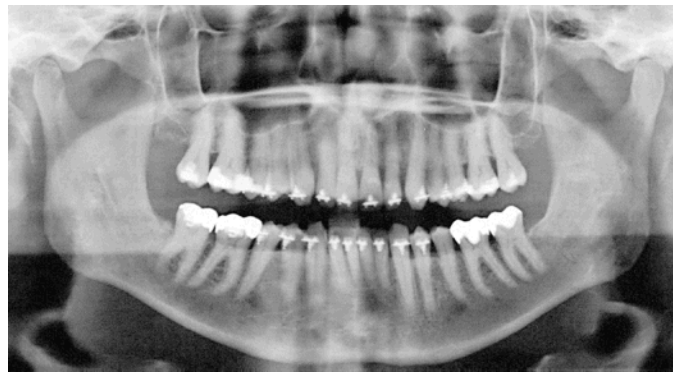


The ALF is used to correct cranial distortions, level the transverse plane and erupt posterior teeth.





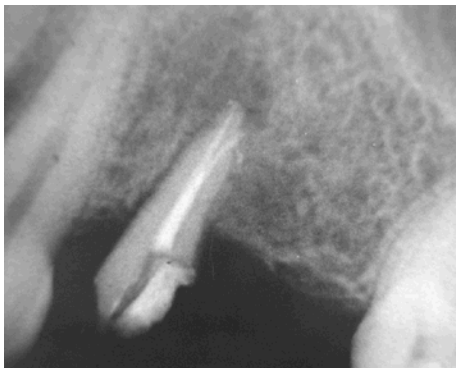After occlusal/cranial alignment was achieved via the OCB Technique, a T-Scan reading was performed. The recorded contacts verify that balance of the four cranial indicators used in treatment represents the most ideal occlusally generated pressure for maximum closure. It should be understood that achieving a balanced T-Scan reading does not necessarily guarantee a balanced cranium.



Tomographic views verify that cranial/dental balance established via use of the OCB Technique provides an anatomically correct condylar position and functional working joint relationship.

Case 5. ALS dental connection

Seventy percent of medically related issues have a dental origin. Julie E. was diagnosed with ALS in 2003. The dental history noted that root canal therapy was performed in the maxillary left first premolar fourteen months before her ALS symptoms started appearing. For the past seven months the patient has been confined to a wheelchair and lost the ability to stand unassisted for any length of time or move her hands. This patient was examined by every top ALS medical specialist in the United States with no diagnosis of any underlying cause. Dental examination incorporating Direct Resonance testing determined the presence of a cytomegalovirus (CMV) in the apical lesion of the root canal tooth. CMV was also present in her thyroid gland and frontal lobe of the brain. In addition, Julie presented with a distorted cranial alignment as diagnosed using the four cranial indicators. Treatment involved placement of two “shims” to restore proper contact in the maxillary right and lower left first molars. In addition, the patient was placed on natural immune stimulators, antioxidants and bio-frequencies for the CMV virus. By the third consecutive treatment day, the patient was able to totally stand unassisted for five plus minutes, walk with assistance and move her hands and fingers and able to touch her nose. These physical acts were unattainable when the patient presented herself on the initial evaluation.



Conclusion

It is this author's belief that the OCB concept represents one of the principal functions of occlusion and is an essential process for restoring and maintaining health. It has been this author's clinical experience that employing the above principles have resolved many difficult cases that have defied traditional medical and dental treatment. Adopting OCB in this author's opinion will help establish the dental profession as a major specialty within the medical/dental profession.

Infected root canal teeth have the potential of causing degenerative illnesses in any region of the body.

References

1. Hubbard, R. P.: "Flexure of Layered Cranial Bone," *J. Biomechanics*, Vol. 4, pp. 351-363, 1971.
2. Michael, David, K., and Retzlaff, Ernst, W.: "A Preliminary Study of Cranial Bone Movement in the Squirrel Monkey," *The J. Amer. Osteopathic Assoc.*, Vol. 74, May 1975.
3. Tettambel, Melicien, et al.: "Recording of the Cranial Rhythmic Impulse," *The J. Osteopathic Assoc.*, Oct. 1978.
4. Upledger, John E., D.O., Retzlaff, Ernest W., Ph.D. and Vredevoord, M.F.A.: "Diagnosis and Treatment of Temporoparietal Suture Head Pain," *Osteopathic Medicine*, pp. 19-26, July 1978.
5. Babler, W. J., Persing, J. A.: "Experimental Alteration of Cranial Suture Growth: Effects on the Neurocranium, Basic Cranium, and Midface," *Factors and Mechanisms Influencing Bone Growth*, Alan R. Lias, Inc., New York, NY 10011, pp. 333-345, 1982.
6. Behrents, R. G., Carlson, D.S., Ardelnous, T.: "In Vivo Analysis of Bone Strain About the Sagittal Suture in Macatta Mulatta during Masticatory Movements," *J. Dent. Res.*, Vol. 57, No. 9-10, pp. 904-908, 1978.
7. Meikle, M. C., Sellers, A., Reynolds, J. J.: "Effects of Tensile Mechanical Stress on the Synthesis of Metalloproteinases by Rabbit Coronal Sutures in Vitro," *Calcif. Tissue Int.*, Vol. 30, pp. 77-82, 1980.
8. Meikle, M. C., et al.: "Rabbit Cranial Sutures in Vitro: A New Experimental Model for Studying the Response of Fibrous Joints to Mechanical Stress," *Calif. Tissue Int.*, Vol. 28, pp. 137-144, 1979.
9. Retzlaff, E., et al.: "Aging of Cranial Sutures in Macaca Nemestria," *Anatomical Records – 91st Session of the Association of Anatomists*, p. 520, 1978.
10. Retzlaff, Ernest, et al.: "Aging of Cranial Sutures in Humans," *Anatomical Records – 92nd Session of the Association of Anatomists*, p. 663, 1979.
11. Foley, W. J., Kokich, V. G.: "The Effects of Mechanical Immobilization on Sutural Development in the Growing Rabbit," *J. Neurosurg.*, Vol. 53, pp. 794-801, 1980.
12. Todd, T. Wingate and Lyon, D. W.: "Cranial Sutural Closure – Its Progress and Age Relationship, Part I-IV," *Am. J. Phys. Anthropol.*, Vol. 7, pp. 324-384, Vol. 8, pp. 23-71, pp. 149-168, 1924-25.
13. Smith DDS, Gerald, H.: "Alternative Treatment For Conquering Chronic Pain," ICNR, Inc. 2000.
14. De Jarnette DC, Major B.: *Cranial Technique 1979-1980*. Self published.
15. De Jarnette DC, Major B.: *Sacro Occipital Technic 1984*. Self published.
16. Gehin, Alain: *Atlas of Manipulative Techniques for the Cranium & Face*. Eastland Press, Seattle, WA., 1981.
17. Carlson DDS, James, E.: *Orthocranial Occlusion and the Accu-Liner System*. Accu-Liner Systems, Woodinville, WA., 1997.